

Essentials for students



plastic surgery

**AMERICAN SOCIETY OF PLASTIC SURGEONS
YOUNG PLASTIC SURGEONS STEERING COMMITTEE**

Lynn Jeffers, MD, Chair
C. Bob Basu, MD, Vice Chair

Eighth Edition 2012

Essentials for Students Workgroup

Lynn Jeffers, MD
Adam Ravin, MD
Sami Khan, MD
Chad Tattini, MD
Patrick Garvey, MD
Hatem Abou-Sayed, MD
Raman Mahabir, MD
Alexander Spiess, MD
Howard Wang, MD
Robert Whitfield, MD
Andrew Chen, MD
Anureet Bajaj, MD
Chris Zochowski, MD

**UNDERGRADUATE EDUCATION COMMITTEE OF THE
PLASTIC SURGERY EDUCATIONAL FOUNDATION**

First Edition 1979

Ruedi P. Gingrass, MD, Chairman
Martin C. Robson, MD
Lewis W. Thompson, MD
John E. Woods, MD
Elvin G. Zook, MD

Copyright © 2012 by the American Society of Plastic Surgeons
444 East Algonquin Road
Arlington Heights, IL 60005

All rights reserved.

Printed in the United States of America

ISBN 978-0-9859672-0-8

INTRODUCTION

This book has been written primarily for medical students, with constant attention to the thought, "Is this something a student should know when he or she finishes medical school?" It is not designed to be a comprehensive text, but rather an outline that can be read in the limited time available in a burgeoning curriculum. It is designed to be read from beginning to end. Plastic surgery had its beginning thousands of years ago, when clever surgeons in India reconstructed the nose by transferring a flap of cheek and then forehead skin. It is a modern field, stimulated by the challenging reconstructive problems of the unfortunate victims of the World Wars. The advent of the operating microscope has thrust the plastic surgeon of today into the forefront of advances in small vessel and nerve repair, culminating in the successful replantation of amputated parts as small as distal fingers. Further, these techniques have been utilized to perform the first composite tissue transplantations of both hands and partial faces. The field is broad and varied and this book covers the many areas of involvement and training of today's plastic surgeons. The American Society of Plastic Surgeons is proud to provide complimentary copies of the Plastic Surgery *Essentials for Students* handbook to all third year medical students in the United States and Canada.

Continually updated information about various procedures in plastic surgery and other medical information of use to medical students and other physicians can be found at the ASPS/PSF website at www.plasticsurgery.org and the Plastic Surgery Education Network at www.psenetwork.org. The information in this book has also been converted to an app in the Android Market and the Apple App store under the name Plastic Surgery Essentials for Students.

TABLE OF CONTENTS

Preface: A Career in Plastic Surgery.....	i
Chapter 1: Wounds.....	1
Chapter 2: Grafts and Flaps.....	9
Chapter 3: Skin and Subcutaneous Lesions.....	16
Chapter 4: Head and Neck.....	26
Chapter 5: Breast, Trunk and External Genitalia.....	43
Chapter 6: Upper Extremity.....	55
Chapter 7: Lower Extremity.....	68
Chapter 8: Thermal Injuries.....	75
Chapter 9: Aesthetic Surgery.....	92
Chapter 10: Body Contouring.....	99

PREFACE

A CAREER IN PLASTIC SURGERY

Originally derived from the Greek "plastikos" meaning to mold and reshape, plastic surgery is a specialty which adapts surgical principles and thought processes to the unique needs of each individual patient by remolding, reshaping and manipulating bone, cartilage and all soft tissues. Not concerned with a given organ system, region of the body, or age group, it is best described as a specialty devoted to the solution of difficult wound healing and surgical problems, having as its ultimate goal the restoration or creation of the best function, form and structure of the body with a superior aesthetic appearance ultimately enhancing a patient's quality of life.

Plastic surgeons emphasize the importance of treating the patient as a whole. Whether reconstructing patients with injuries, disfigurements or scarring, or performing cosmetic procedures to recontour facial and body features not pleasing to the patient, plastic surgeons are concerned with the effect of the outcome on the entire patient. Not necessarily concerned with a set and limited repertoire of surgical procedures, plastic surgery is more a perspective and set of principles with the ultimate goal of solving problems and thus, exposure to a wide variety of surgical problems and disciplines enhance the ability of the plastic surgeon to care for all patients.

The challenge of plastic surgery then is the combination of the surgeon's judgment and problem solving abilities with surgical technique at any given moment. Because of this approach, the plastic surgeon often acts as a "last resort" surgical consultant to surgeons and physicians in the treatment of many wound problems and is often called "the surgeon's surgeon."

Plastic surgery not only restores body function, but helps to renew or improve a patient's body image and sense of self-esteem. Along with psychiatrists, plastic surgeons are especially equipped to handle the patient's problem of body image and to help the patient deal with either real or perceived problems.

Consistent with these far reaching goals, the scope of the operations performed by plastic surgeons is broad. As outlined by The American Board of Plastic Surgery," the specialty of plastic surgery deals with the repair, replacement, and reconstruction of physical defects of form or function involving the skin, musculoskeletal system, craniomaxillofacial structures, hand, extremities, breast and trunk, and external genitalia. It uses aesthetic surgical principles not only to improve undesirable qualities of normal structures, but in all reconstructive procedures as well. Among the problems managed by plastic surgeons are congenital anomalies of the head and neck. Clefts of the lip and palate are the most common, but many other head and neck congenital deformities exist. In addition, the plastic surgeon treats injuries to the face, including fractures of the bone of the jaw and face.

Craniofacial surgery is a discipline developed to reposition and reshape the bones of the face and skull through inconspicuous incisions. Severe deformities of the cranium and face, which previously were uncorrectable or corrected with great difficulty, can now be better reconstructed

employing these new techniques. Such deformities may result from a tumor resection, congenital defect, previous surgery, or previous injury. Treatment of tumors of the head and neck and reconstruction of these regions after the removal of these tumors is also within the scope of plastic surgery.

Another area of expertise for the plastic surgeon is hand surgery, including the management of acute hand injuries, the correction of hand deformities and reconstruction of the hand. Microvascular surgery, a technique that allows the surgeon to connect blood vessels of one millimeter or less in diameter, is a necessary skill in hand surgery for re-implanting amputated parts or in moving large pieces of tissue from one part of the body to another.

Defects of the body surface resulting from burns or from injuries, previous surgical treatment, or congenital deformities may also be treated by the plastic surgeon. One of the most common of such procedures is reconstruction of the breast following mastectomy. Breasts may also be reduced in size, increased in size, or changed in shape to improve the final aesthetic appearance. Operations of this type are sometimes cosmetic in purpose, but in cases where the patient has a significant asymmetry or surgical defect, the procedure serves important therapeutic purposes.

The most highly visible area of plastic surgery is aesthetic or cosmetic surgery. Cosmetic surgery includes facelifts, breast enlargements and enhancement, nasal surgery, body sculpting, and other similar operations to enhance one's appearance.

The results of the plastic surgeon's expertise and ability are highly visible, leading to a high degree of professional and personal satisfaction. Plastic surgery is an innovative specialty.

Advances such as transplantation, microvascular surgery, fat grafting, and various medical devices have been spearheaded and advanced by plastic surgeons. The discipline requires meticulous attention to detail, sound judgment and technical expertise in performing the intricate and complex procedures associated with plastic surgery. In addition, plastic surgeons must possess a flexible approach that will enable them to work on a daily basis with a tremendous variety of surgical problems. Most importantly, the plastic surgeon must have creativity, curiosity, insight, and an understanding of human psychology.

Because of the breadth of the specialty and its ever changing content, opportunities for individuals with varied backgrounds is particularly important. Individuals with undergraduate majors ranging from art to engineering find their skills useful in various areas of plastic surgery. This need for a broad education continues into medical school.

Students should use elective time to acquire the broadest base of medical knowledge. Experience in surgery and psychiatry are of particular value. Clinical rotations in surgical specialties, such as neurosurgery, orthopaedics, otolaryngology, pediatric surgery, transplantation, or urology may prove more valuable than general surgery since most of the early residency experience will be in general surgery.

While there are several approved types of prerequisite surgical education, most candidates for the traditional plastic surgery residency programs have had from three to five years of training in general surgery after graduating from medical school. Applicants may also apply for a plastic

surgery residency after completing a residency in otolaryngology, orthopaedics, neurosurgery, or urology. Plastic surgery residency in the traditional format is generally for three years. In the newer Integrated Residency programs, applicants apply to start immediately following graduation from medical school and will have either six years of training under the leadership of the program director of plastic surgery. Following residency training, some plastic surgeons spend an additional six to twelve months of fellowship training in a particular area of plastic surgery such as craniofacial surgery, aesthetic surgery, hand surgery, or microsurgery.

The American Board of Plastic Surgery (ABPS) issues a Booklet of Information each year which outlines the training and requirements for eligibility to take the examinations offered by the board. You may request information from ABPS at:

The American Board of Plastic Surgery, Inc.
Seven Penn Center, Suite 400
1635 Market Street
Philadelphia, PA 19103-2204
Phone: 215-587-9322
Fax: 215-587-9622
Email: info@abplsurg.org
Online: www.abplsurg.org

Traditionally, plastic surgeons have established their practices in large urban settings. However, there is an increasing need for more plastic surgeons in the smaller communities and rural areas of this country - many metropolitan areas with populations of 65,000 to 268,000 have no plastic surgeons, leaving a large number of areas needing plastic surgery expertise. There are approximately 6,000 board certified plastic surgeons in the United States; many of those currently certified by The American Board of Plastic Surgery received certification in the past ten years. Despite this recent rapid growth, there are opportunities for plastic surgeons in community and academic practice.

Plastic surgery is an old specialty with references that date back thousands of years. It has survived and flourished because it is a changing specialty built by imaginative, creative and innovative surgeons with a broad background and education.

The limit of the specialty is bound only by the imagination and expertise of those in its practice. The opportunities for the future are open to those who wish to be challenged.

ADDITIONAL RESOURCES ON THE SPECIALTY OF PLASTIC SURGERY

- I. American Society of Plastic Surgeons
444 East Algonquin Road
Arlington Heights, IL 60005-4664
Phone: 847-228-9900
Fax: 847-228-9131
www.plasticsurgery.org
www.facebook.com/PlasticSurgeryASPS
- II. Plastic Surgery Research Council
Suite 304
45 Lyme Road
Hanover, NH 03755
Phone: 603-643-2325
www.ps-rc.org
- III. Residency Review Committee for Plastic Surgery
515 North State Street, Suite 2000
Chicago, IL 60610
Phone: 312-464-5586
Fax: 312-464-4098

CHAPTER 1

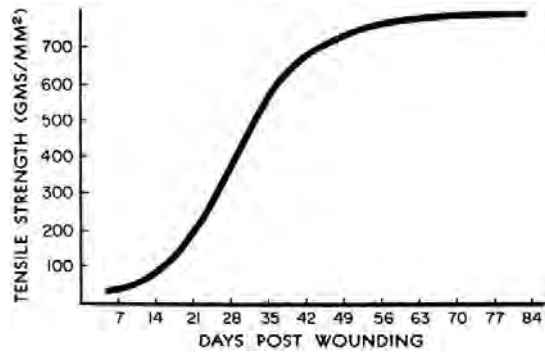
WOUNDS

A wound can be defined as a disruption of the normal anatomical relationships of tissues as a result of injury. The injury may be intentional such as a surgical incision or accidental following trauma. Immediately following wounding, the healing process begins.

I. STAGES OR PHASES OF WOUND HEALING

Regardless of type of wound healing, stages or phases are the same except that the time required for each stage depends on the type of healing and other local factors that may influence wound closure (foreign body, infection, etc).

- A. *Substrate* phase (inflammatory, lag or exudative stage or phase - days 1-4)
 1. *Symptoms* and signs of inflammation
 - a. Redness(*rubor*), heat(*calor*), swelling(*tumor*), pain(*tumor*), and loss of function
 2. Physiology of inflammation
 - a. Leukocyte margination, sticking, emigration through vessel walls
 - b. Venule dilation and lymphatic blockade
 - c. Neutrophil chemotaxis and phagocytosis
 3. Removal of clot, debris, bacteria, and other impediments of wound healing
 4. Lasts finite length of time (approximately four days) in primary intention healing
 5. Continues until wound is closed (unspecified time) in secondary and tertiary intention healing
- B. Proliferative phase (collagen and fibroblastic stage or phase - approximately days 4-42)
 1. Synthesis of collagen tissue from fibroblasts
 2. Increased rate of collagen synthesis for 42-60 days
 3. Rapid gain of tensile strength in the wound (see Fig. 1-1)
- C. Remodeling phase (maturation stage or phase - from approximately three weeks onward)
 1. Maturation by intermolecular cross-linking of collagen leads to flattening of scar
 2. Requires approximately 9-12 months in an adult - longer in children (Thus scar revisions may be delayed a year or longer after injury to ensure remodeling is complete)
 3. Dynamic, ongoing
 4. Tensile strength of a healed scar will peak at approximately 60 days post-injury and achieve up to 80% of unwounded skin



(Fig. 1-1)

II. WOUND CLOSURE

- A. Primary healing (by primary intention) - wound closure by direct approximation, pedicle flap or skin graft
 1. Debridement of non-viable tissue and irrigation of the wound can minimize inflammation which will facilitate the healing process
 2. Dermis should be accurately approximated with sutures and is the strength layer of the wound repair (see chart at end of chapter) or skin glue if the wound is limited to partial thickness depth (i.e., cyanoacrylate or histoacryl products)
 3. Scar may be red, raised, pruritic, and angry-looking at peak of collagen synthesis
 4. Thinning, flattening and blanching of scar occurs over approximately 9-12 months in adults, as collagen maturation occurs (may take longer in children)
 5. Final result of scar depends largely on how the dermis was approximated and can be influenced by tension of the closure, location and presence or absence of complicating environmental factors
- B. Spontaneous healing (by secondary intention) - wound left open to heal spontaneously - maintained in inflammatory phase until wound closed
 1. Spontaneous wound closure depends on contraction and epithelialization
 2. Contraction results from centripetal force in wound margin probably provided by myofibroblasts
 3. Epithelialization proceeds from wound margins towards center at 1 mm/day
 4. Although contraction (the process of contracting) is normal in wound healing, one must beware of contracture (an end result - may be caused by contraction of scar and is a pathological deformity)
 5. Secondary healing beneficial in some wounds, e.g. perineum, heavily contaminated wounds, scalp
- C. Tertiary healing (by tertiary intention) - delayed wound closure after several days

1. Distinguishing feature of this type of healing is the intentional interruption of healing begun as secondary intention
2. Can occur any time after granulation tissue has formed in wound
3. Delayed closure should be performed when wound is not infected (usually 10⁵ or fewer bacteria/gram of tissue on quantitative culture except with beta-STREP)

III. FACTORS INFLUENCING WOUND HEALING

- A. Local factors most important because we can control them
 1. Tissue trauma - must be kept at a minimum
 2. Hematoma - associated with higher infection rate
 3. Blood supply
 4. Temperature
 5. Infection
 6. Technique and suture materials - only important when factors 1-5 have been controlled
- B. General factors - cannot be readily controlled by surgeon; systemic effects of steroids, nutrition, chemotherapy, chronic illness, etc., contribute to wound healing

IV. MANAGEMENT OF THE CLEAN WOUND

- A. Goal - obtain a closed wound as soon as possible to prevent infection, fibrosis and secondary deformity
- B. General principles
 1. Immunization - use American College of Surgeons Committee on Trauma recommendation for tetanus immunization
 2. If necessary, use pre-anesthetic medication to reduce anxiety while adhering to proper monitoring and safety measures to prevent medication related complications
 3. Local anesthesia - use amide ester (Lidocaine) with epinephrine unless contraindicated, e.g. tip of penis, fingertip
 4. Tourniquet to provide bloodless field in extremities
 5. Cleansing of surrounding skin - do NOT use strong antiseptic in the wound itself that may interfere with re-epithelialization or collagen synthesis
 6. Debridement
 - a. Remove clot and debris, necrotic tissue
 - b. Copious irrigation good adjunct to sharp debridement
 7. Closure - use atraumatic technique to approximate dermis. Consider undermining of wound edges to relieve tension
 8. Dressing - must provide absorption, protection, immobilization, even compression, and be aesthetically acceptable
- C. Types of wounds and their treatment
 1. Abrasion - cleanse to remove foreign material
 - a. Consider scrub brush or dermabrasion to remove dirt buried in dermis to prevent traumatic tattoos (permanent discoloration due to buried dirt beneath new skin surface) - needs to be accomplished within 24 hours of injury
 2. Contusion - consider need to evacuate hematoma if collection is present or if pressure of hematoma is compromising surrounding tissue
 - a. Early - minimize by cooling with ice (24-48 hours)

- b. Later - warmth to speed absorption of blood
 - 3. Laceration - trim wound edges if necessary (ragged, contused) and suture
 - 4. Avulsion
 - a. Partial (creates a flap) - revise and suture if viable
 - b. Total - do not replace totally avulsed tissue except as a skin graft after fat is removed
 - 5. Puncture wound - evaluate underlying damage, possibly explore wound for foreign body, etc.
 - 6. Animal bites - debride and close primarily or leave open, depending upon anatomic location, time since bite, etc. Use antibiotics
- D. Wounds of face
- 1. Important to use careful technique
 - a. Urgency should not override judgment
 - b. There is a longer "period of grace" during which the wound may be closed since blood supply to face is excellent
 - c. Do not forget about other possible injuries (chest, abdomen, extremities). Very rare for patient to die from facial lacerations alone
 - 2. Facial lacerations of secondary importance to airway problems, hemorrhage or intracranial injury
 - 3. Beware of overaggressive debridement of questionably viable tissue. May consider serial exams and closure to determine viability of tissue
 - 4. Isolate cavities from each other by suturing linings, such as oral and nasal mucosa
 - 5. Use anatomic landmarks to advantage, e.g. alignment of vermilion border, nostril sill, eyebrow, helical rim
- E. Wounds of the upper extremity (See Chapter 6)
- F. Special Wounds
- 1. Amputation of parts
 - a. Attempt replacement if within six hours of injury
 - b. Place amputated part in saline soaked gauze in a plastic bag and the bag in ice. Protect tissue from direct contact with ice to prevent thermal injury
 - 2. Cheek injury - examine for parotid duct and/or facial nerve injury
 - 3. Intraoral injuries - tongue, cheek, palate, and lip wounds require suturing
 - 4. Eyelids - align grey line and close in layers - consider temporary tarsorrhaphy
 - 5. Ear injuries
 - a. Hematoma - incision and drainage of hematoma and well-molded dressing to prevent cauliflower ear deformity
 - b. Through-and-through laceration requires 3 layer closure including cartilage
 - 6. Animal bites - debridement, irrigation, antibiotics, and possible wound closure. Be particularly careful of cat bites which can infect with a very small puncture wound
- V. MANAGEMENT OF THE "CONTAMINATED" WOUND
- A. Guidelines for management of contaminated acute wounds
- 1. Majority of civilian traumatic wounds can be closed primarily after adequate debridement
 - a. Adequate debridement
 - i. Mechanical/sharp or chemical/enzymatic (eg. Collagenase, Panafil®)

- ii. Irrigation - copious pulsatile lavage
 - b. Exceptions (may opt to leave wound open)
 - i. Heavy bacterial inoculum (human bites)
 - ii. Long time lapse since wounding (relative)
 - iii. Crushed or ischemic tissue - severe contused avulsion injury
 - iv. Sustained high-level steroid ingestion (some animal studies indicate that oral administration of Vitamin A (retinoic acid) can mitigate some of the effects of steroids on wound healing).
 - 2. Antibiotics - Systemic antibiotics are only of use if a therapeutic tissue level can be reached within four hours of wounding or debridement
 - 3. Wound closure
 - a. Buried sutures should be used to keep wound edge tension to a minimum; however, each suture is a foreign body which increases the chance of infection (use least number of sutures possible to bring wound together without tension)
 - b. Skin sutures of monofilament material are less apt to become infected
 - c. Porous tape closure may be used for some wounds
 - 4. Follow up - contaminated traumatic wounds should be checked for infection within 48 hours after closure
 - 5. If doubt exists, it is always safer to delay closure (revision can be done later)
- B. Guidelines for management of contaminated chronic wounds
- 1. Examples - wounds greater than 24 hours old
 - a. Common ingredient - granulation tissue
 - 2. Debridement as important as in an acute wound
 - a. Excision (scalpel, scissors)
 - b. Frequent dressing changes
 - c. Enzymatic - seldom indicated
 - 3. Systemic antibiotics of little use
 - 4. Topical antibacterial creams - silver sulfadiazine (Silvadene™) and mafenide acetate (Sulfamylon™)
 - a. Continual surface contact
 - b. Good penetrating ability
 - c. Decrease bacterial counts of wounds
 - 5. Biological dressings (allograft, xenograft, some synthetic dressings) debride wound, decrease pain.
 - 6. Final closure
 - a. With a delayed flap, skin graft or flap
 - b. Convert the chronic contaminated wound bacteriologically to an acute clean wound by decreasing the bacterial count (debridement)

VI. WOUND DRESSINGS

- A. Protect the wound from trauma
- B. Provide environment for healing
- C. Antibacterial medications
 - 1. Bacitracin® and Neosporin®
 - a. Provide moist environment conducive to epithelialization. Beware of secondary inflammatory reaction from antibiotic cream that may mimic infection

- 2. Silver sulfadiazine (Silvadene®) and mafenide acetate (Sulfamylon®)
 - a. Useful for burns or other wounds with an eschar
 - b. Antibacterial activity penetrates eschar
- D. Splinting and casting
 - 1. For immobilization to promote healing
 - 2. Do not splint too long - may promote joint stiffness
- E. Pressure Dressings
 - 1. May be useful to prevent “dead space” (potential space in wound) or to prevent seroma/hematoma
 - 2. Do not compress flaps tightly
- F. Do not leave dressing on too long (<48 hours) before changing

VII. NEGATIVE PRESSURE WOUND THERAPY (NPWT)

Relatively new dressing that may be beneficial tool for large wounds or contaminated wounds that are not amenable to primary closure (V.A.C.TM therapy –KCI, San Antonio, TX, Chariker-JeterTM Smith and Nephew, PLC, London, UK)

- A. Technique includes application of foam sponge or gauze covered with adhesive dressing applied to vacuum device that provides subatmospheric pressure (-50 to -175mmHg)
 - 1. Should not be placed in direct contact with blood vessels or other fragile structures. Also should not be used in grossly purulent or necrotic wounds
 - 2. Dressing should be changed every 48-72 hours to assess wound progress and viability of tissue
- B. Mechanism of Action
 - 1. Maintains a moist wound environment and reduces edema
 - 2. Increases local wound blood flow, reduces presence of inflammatory mediators, and may speed overall collagen synthesis and rate of wound closure
- C. Disadvantages include cost of device, pain with dressing changes and peri-wound irritation secondary to adhesive drape
- D. Can be used as adjunct dressing to serve as bolster for skin grafts, and provide exudative management for draining wounds

SUTURE & COMPOSITION	ETHICON® Synthetic Absorbable Sutures			FREQUENT USES	MAIN BENEFIT
	COLOR & TYPE	BNR	ABSORPTION RATE		
Coated VICRYL RAPIDE® (polyglactin 910) suture	Undyed Braided	50% at 5 days 0% at 10 to 14 days	Essentially complete by 42 days	Skin and Mucosa: <ul style="list-style-type: none"> - Episiotomy repair - Lacerations under casts - Mucosa in oral cavity - Skin repairs where rapid absorption is desired, excluding joints and high stress areas 	Patient comfort No suture removal
MONOCRYL® (polylactoprone 25) suture	Undyed/Dyed (Violet) Monofilament	Dyed: 60 to 70% at 7 days 30 to 40% at 14 days Undyed: 50 to 60% at 7 days 20 to 30% at 14 days	Essentially complete between 91 and 119 days	Soft Tissue Approximation: <ul style="list-style-type: none"> - Ligation - Skin Repairs - Pericardium - Peritoneum - Uterus - Vaginal Cuff 	Unprecedented monofilament pliability Smooth tissue passage
Coated VICRYL suture	Undyed/Dyed (Violet) Braided	75% at 14 days 50% at 21 days† 40% at 21 days‡	Essentially complete between 65 and 70 days	Soft Tissue Approximation: <ul style="list-style-type: none"> - Ligation - Closure - Ophthalmic Surgery - Orthopaedic Surgery - Bowel 	Strength, preferred performance and handling Knot security
IPS® II (polydioxanone) suture	Undyed/Dyed (Violet) Monofilament	70% at 14 days 50% at 28 days 25% at 42 days	Essentially complete within 6 months	Soft Tissue Approximation: <ul style="list-style-type: none"> - Esophagus - Orthopaedic Surgery - Blood Vessel Anastomoses - Pediatric Cardiovascular and Ophthalmic procedures - Patients with compromised wound healing conditions 	Longest lasting absorbable monofilament wound support Outstanding pliability

*Trademark † Sizes 6/0 and larger ‡ Sizes 7/0 and larger

CHAPTER 1 – BIBLIOGRAPHY

WOUNDS

1. Alster, T.S., and West, T.B. Treatment of scars: a review. *Ann Plast Surg.* 1997; 39:418-32.
2. Eppley, B.L. Alloplastic Implantation. *Plast Reconstr Surg.* 1999; 104:1761-83.
3. Hunt, T.K., et al. Physiology of wound healing. *Adv Skin Wound Care.* 2000; 13 (suppl 6-11).
4. Klein, A.W. Collagen substitutes: bovine collagen. *Clin Plast Surg.* 2001; 28:53-62.
5. Lawrence, W.T. Physiology of the acute wound. *Clin Plast Surg.* 1998; 25: 321-40.
6. Mast, B.A., Dieselmann, R.F., Krummel, T.M., and Cohen, I.K. Scarless wound healing in the mammalian fetus. *Surg. Gynecol. Obstet.* 1992; 174:441.
7. Nwomeh, B.C., Yager, D.R., Cohen, K. Physiology of the chronic wound. *Clin Plast Surg.* 1998; 25:3.
8. Saltz, R. and Zamora, S. Tissue adhesives and applications in plastic and reconstructive surgery. *Aesthetic Plast Surg.* 1998; 22:439-43.
9. Stadleman, W.K., Digenis, A.G., and Tobin, G.R. Physiology and healing dynamics if chronic cutaneous wounds. *Am J Surg.* 1998; 176:26S-38S.
10. Terino, E.O. Aloderm acellular dermal graft: applications in aesthetic soft tissue augmentation. *Clin Plast Surg.* 2001; 28:8399.
11. Witte, M.B., and Barbul, A. General principles of wound healing. *Surg Clin North Am.* 1997; 77:509-28.
12. Venturi M.L., Attinger C.E., Mesbahi A.N., et al. Mechanisms and clinical applications of the vacuum assisted closure (VAC) device: a review. *Am J Clin Dermatol* 2005; 6:185.
13. Ubbick D.T., Westerbos S.J, Nelson E.A., Vermeulen H. A systematic review of topical negative pressure therapy for acute and chronic wounds. *Br J Surg* 2008; 95:685.

CHAPTER 2

GRAFTS AND FLAPS

When a deformity needs to be reconstructed, either grafts or flaps can be employed to restore normal function and/or anatomy. For instance, when wounds cannot be closed primarily or allowed to heal by secondary intention, either grafts or flaps can be used to reconstruct an open wound.

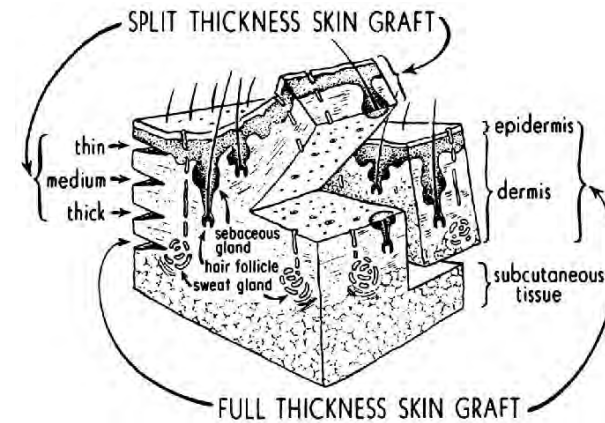
GRAFTS

Grafts are harvested from a donor site and transferred to the recipient site without carrying its own blood supply. It relies on new blood vessels from the recipient site bed to be generated (angiogenesis).

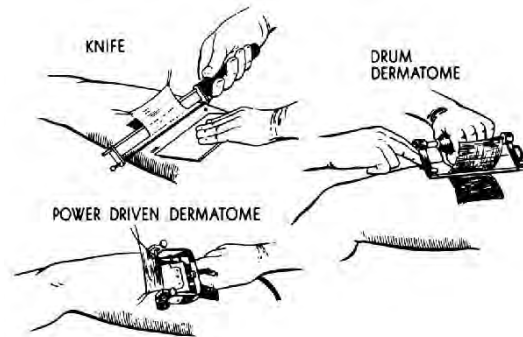
I. SKIN GRAFTS

A. Thickness (Figure 2-1)

1. Full thickness- Full thickness skin grafts (FTSGs) consist of the entire epidermis and dermis.
2. Split thickness- Split thickness skin grafts (STSGs) consist of the epidermis and varying degrees of dermis. They can be described as thin, intermediate, or thick.
3. Harvested using a dermatome or freehand. (Figure 2-2)



(FIGURE 2-1)



(FIGURE 2-2)

- B. Donor site**
1. Full thickness- The full thickness skin graft leaves behind no epidermal elements in the donor site from which resurfacing can take place. Thus, the donor site of a FTSG must be closed. It must be taken from an area that has skin redundancy. It is usually harvested with a knife between the dermis and the subcutaneous fat.
 2. Split thickness- The split thickness skin graft leaves behind adnexal remnants such as hair follicles and sweat glands, foci from which epidermal cells can repopulate and resurface the donor site. It is usually harvested with either a special blade or dermatome that can be set to a desired thickness.
- C. Recipient site**
1. Full thickness- Full thickness skin grafts are usually used to resurface smaller defects because they are limited in size. It is commonly used to resurface defects of the face. It provides a better color consistency, texture, and undergoes less secondary contraction.
 2. Split thickness- Split thickness grafts are usually used to resurface larger defects. Depending on how much of the dermis is included, STSGs undergo secondary contraction as it heals.
- D. Survival**
1. Full thickness and split thickness skin grafts survive by the same mechanisms.
 - a. Plasmatic imbibition (First 24-48 hours)- Initially, the skin grafts passively absorb the nutrients in the wound bed by diffusion.
 - b. Inosculation- By day 3, the cut ends of the vessels on the underside of the dermis begin to form connections with those of the wound bed.

- c. Angiogenesis- By day 5, new blood vessels grow into the graft and the graft becomes vascularized.
2. Skin grafts fail by four main mechanisms
 - a. Poor wound bed- Because skin grafts rely on the underlying vascularity of the bed, wounds that are poorly vascularized with bare tendons or bone, or because of radiation, will not support a skin graft.
 - b. Sheer- Sheer forces separate the graft from the bed and prevent the contact necessary for revascularization and subsequent "take", which refers to the process of attachment and revascularization of a skin graft in the donor site
 - c. Hematoma/seroma- Hematomas and seromas prevent contact of the graft to the bed and inhibit revascularization. They must be drained by day 3 to ensure "take."
 - d. Infection- Bacteria have proteolytic enzymes that lyse the protein bonds needed for revascularization. Bacterial levels greater than 10⁵ are clinically significant.
 - E. Substitutes

These usually provide temporary coverage; They require an adequately vascularized recipient bed

 1. Allograft/Alloderm- Cadaveric skin or dermis
 2. Xenograft- Skin from a different species, ie pig skin
 3. Synthetic- Biobrane, Integra

II. OTHER GRAFTS

- A. Nerve
- B. Fat
- C. Tendon
- D. Cartilage
- E. Bone
- F. Muscle
- G. Composite- A graft that has more than one component, i.e. cartilage and skin graft, dermal-fat graft

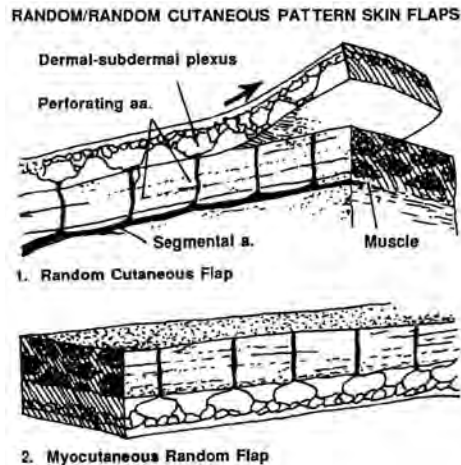
FLAPS

Flaps are elevated from a donor site and transferred to the recipient site with an intact vascular supply. It survives by carrying its own blood supply until new blood vessels from the recipient site are generated at which time the native blood supply (pedicle) can be divided. Flaps can be used when the wound bed is unable to support a skin graft or when a more complex reconstruction is needed.

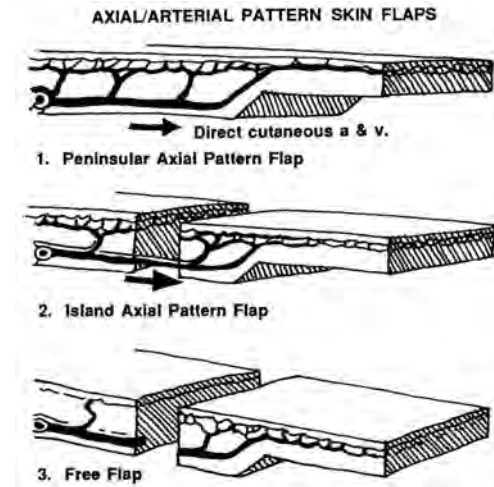
I. CLASSIFICATION

- A. By composition- Flaps can be classified by the type of tissue transferred.
 1. Single component
 - a. Skin flap- i.e. Parascapular flap
 - b. Muscle flap- i.e. Rectus muscle flap or latissimus dorsi muscle flap
 - c. Bone flap- i.e. Fibula flap
 - d. Fascia flap- i.e. Serratus fascia flap
 2. Multiple components

- a. Fasciocutaneous- Radial forearm flap or anterolateral thigh flap
 - b. Myocutaneous- Transverse rectus abdominis myocutaneous flap
 - c. Osseoseptocutaneous- Fibula with a skin paddle
- B. By location- Flaps can be described by the proximity to the primary defect that needs to be reconstructed. The harvest leaves a secondary defect that needs to be closed.
1. Local flaps- Local flaps are raised from the tissue adjacent to the primary defect. Its movement into the defect can be described as advancement, rotation, or transposition. Specific examples of local skin flaps are the V-Y, rhomboid, and bilobed flaps.
 2. Regional- Regional flaps are raised from tissue in the vicinity but not directly adjacent to the primary defect. The movement is described as transposition or interpolation.
 3. Distant- Distant flaps are raised from tissue at a distance from the primary defect. This usually requires re-anastomosis of the blood vessels to recipient blood vessels in the primary defect. These are called microvascular ("free") flaps.
- C. By vascular pattern
1. Random vs. Axial (Figure 2-3)
 - a. Random pattern flaps do not have a specific or named blood vessel incorporated in the base of the flap. Because of the random nature of the vascular pattern, it is limited in dimensions, specifically in the length: width ratio (3:1).



- b. Axial pattern flaps (Fig. 2-4) are designed with a specific named vascular system that enters the base and runs along its axis. This allows the flap to be designed as long and as wide as the territory the axial artery supplies.
 - i. Blood supply by direct artery and accompanying vein
 - ii. Greater length possible than with random flap
 - iii. Can be free flap (see free flap)
 - iv. Peninsular – skin and vessel intact in pedicle
 - v. Island – vessels intact, but no skin over pedicle



2. Pedicled vs. Free
 - a. Pedicled flaps remain attached to the body at the harvest site. The pedicle is the base that remains attached and includes the blood supply. It is transferred to the defect with its vascular pedicle acting as a leash. Usually via a musculocutaneous or fasciocutaneous fashion.
 - b. Free flaps are detached at the vascular pedicle and transferred from the donor site to the recipient site. They require re-anastomosis of the artery and vein to recipient vessels at the recipient site.
3. Perforator- Perforator flaps are flaps consisting of skin and/or subcutaneous fat supplied by vessels that pass through or in between deep tissues. It is harvested without the deep tissues in order to minimize donor site morbidity and to yield only

the necessary amount of skin and/or subcutaneous fat for transfer. It can be transferred either as a pedicled or free flap.

- a. Deep inferior epigastric perforator flap- DIEP flap consists of the skin and fat of the lower abdomen supplied by the deep inferior epigastric artery and vein perforators without the rectus abdominis muscle.
- b. Anterolateral thigh perforator flap- The ALTP consists of the skin and fat of the antero-lateral thigh supplied by the descending branch of the lateral circumflex artery and vein perforators without the vastus lateralis muscle.
- c. Thoracodorsal artery perforator flap- The TAP flap consists of the skin and fat of the lateral back supplied by the thoracodorsal artery and vein perforator without the latissimus dorsi muscle.

II. CHOOSING THE RIGHT FLAP

- A. The primary defect- Recipient site considerations
 1. Location and size
 2. Quality and vascularity of surrounding tissues
 3. Presence of exposed structures
 4. Functional and aesthetic considerations
- B. The secondary defect- Donor site considerations
 5. Location
 6. Adhere to the concept of angiosomes, the territory that is supplied by a given vessel
 7. What type of tissues are needed
 8. Functional and aesthetic morbidity

III. SURVIVAL

- A. The success of a flap depends not only on its survival but also its ability to achieve the goals of reconstruction.
- B. The failure of a flap results ultimately from vascular compromise or the inability to achieve the goals of reconstruction.
 1. Tension
 2. Kinking
 3. Compression
 4. Vascular thrombosis
 5. Infection

CHAPTER 2 - BIBLIOGRAPHY

GRAFTS AND FLAPS

1. Mathes, S.J. Reconstructive Surgery: Principles, Anatomy and Techniques. New York, Elsevier Science, 1997.
2. McCarthy, J.G. (ed). Plastic Surgery, vol. 1. New York: Elsevier Science, 1990.
3. Russell, R.C. and Zamboni, W.A. Manual of Free Flaps New York: Elsevier Science, 2001.
4. Serafin, D. Atlas of Microsurgical Composite Tissue Transplantation. New York: Elsevier Science, 1996.

CHAPTER 3

SKIN AND SUBCUTANEOUS LESIONS

Lesions can be categorized into benign or malignant types.

I. BENIGN

A. Scars.

1. Hypertrophic scars. These scars are often misdiagnosed as keloid scars (see below). One can distinguish between hypertrophic and keloid scars as follows:
 - a. Hypertrophic scars are scars confined to the borders of the original incision or traumatic margins.
 - b. Hypertrophic scars may regress spontaneously with time.
 - c. Commonly develop in areas of tension (upper/lower extremities, back, chest).
 - d. No racial predilection.
 - e. Hypertrophic fibroblasts behave as normal fibroblasts in terms of collagen and fibronectin production, as well as in terms of their response to transforming growth factor beta type-1 (TGFβ1).
 - f. Treatment. Scars generally take 18-24 months to mature (reach their final appearance). Therefore hypertrophic scars can be modulated with either or a combination of:
 - i. Constant or intermittent pressure therapy (compression garments or massage)
 - ii. Topical silicone sheeting
 - iii. Intralesional steroid injections (10mg/ml or 40mg/ml triamcinolone, a.k.a. Kenalog-10 or Kenalog-40)
 - iv. Surgical intervention (scar revision) in select cases.
2. Keloid scars. As opposed to hypertrophic scars, keloid scars have the following characteristics:
 - a. Keloid scars are scars that grow beyond the borders of the original incision or traumatic margins.
 - b. Keloid scars do not regress spontaneously with time, and have a high recurrence rate.
 - c. Keloid scars can develop in areas of tension and nontension.
 - d. A racial predilection exists, as keloid scars appear more frequently in Asians and African-Americans compared to Caucasians.
 - e. Keloid fibroblasts produce higher levels of collagen, fibronectin, and are hyperresponsive to TGFβ1.
 - f. Treatment. Keloid scars are difficult to treat, and are often refractory to nonsurgical and surgical therapies. Furthermore, these scars have a high recurrence rate in the setting of the various modalities of treatment
 - i. Intralesional steroids alone (9-50% recurrence rate)
 - ii. Surgery alone (45-100% recurrence rate)
 - iii. Surgery and intralesional steroids (50% recurrence rate)
 - iv. Surgery and radiotherapy (25% recurrence rate).

B. Benign Neoplasms and Hyperplasias.

1. Seborrheic Keratosis
 - a. Most common of the benign epithelial tumors
 - b. Usually hereditary (questionable autosomal dominant pattern)
 - c. Clinically manifest after age 30
 - d. More common in male population
 - e. Progresses from macule (skin-colored or tan lesion in Caucasians), then progresses to plaque (“stuck-on” appearance) that is more pigmented in color. The surface may become “wart-like” and horn cysts, resulting from plugged hair follicles, arise. These cysts are pathognomonic for this keratosis.
 - f. Treatment
 - i. Electrocautery, cryosurgery with liquid nitrogen spray (high recurrence rate)
 - ii. curettage with cryosurgery (optimal modality as this does not destroy cytoarchitecture and permits histopathologic analysis).
2. Keratoacanthoma
 - a. Often confused or misdiagnosed with squamous cell carcinoma
 - b. Clinically manifests in middle years (20-50 years)
 - c. Male: female ratio 2:1
 - d. Caucasians more likely to be affected; rare in Asians and African-Americans
 - e. Isolated nodule that rapidly grows, achieving a size on average of 2.5cm within weeks. Nodule is dome-shaped, firm, red-tan in color, and has a central keratosis that sometimes gives it an umbilicated appearance.
 - f. Anatomical areas of predilection: exposed skin
 - g. DDX: SCC, hypertrophic actinic keratosis, verruca vulgaris
 - h. Lesions often spontaneously regress within 2-12 months.
 - i. Treatment:
 - i. Single lesion: Surgical excision is often recommended (to rule out SCC).
 - ii. Multiple lesions: Retinoids and methotrexate. If no improvement, must excise.
3. Dermatofibroma
 - a. A.k.a. Solitary histiocytoma, sclerosing hemangioma
 - b. Females>males
 - c. Clinically manifests in adulthood
 - d. Button-like dermal nodule, usually develops on the extremities, variable in color. Borders ill-defined. Occasionally tender.
 - e. Lesions may persist or spontaneously regress.
 - f. Treatment: Surgical excision rarely indicated; cryosurgery with liquid nitrogen spray often effective.
4. Skin Tag (a.k.a. Acrochordon, or cutaneous papilla)
 - a. Common; most often present in middle aged or elderly
 - b. Intertriginous areas (axillae, groin, inframammary fold) common sites; also eyelid, neck
 - c. Clinically manifest as soft, skin-colored, pedunculated papilloma or polyp; range in size between 1-10mm. May increase in number and size during pregnancy.
 - d. DDX: Pedunculated seborrheic keratosis, dermal or compound nevus, neurofibroma, or molluscum contagiosum.

- e. Treatment: Simple excision or cryosurgery.
- 5. Trichoepithelioma
 - a. Common during puberty.
 - b. Anatomical sites: face, scalp, neck
 - c. Clinically manifest as small skin-colored or pearl-like lesions, that increase in number and size
 - d. Can be confused with BCC (sclerosing or morpheaform-type0).
 - e. Treatment: Surgical excision for concerning lesions
- 6. Syringoma
 - a. Benign adenoma of intraepidermal eccrine ducts.
 - b. May be familial.
 - c. Anatomical sites: face (eyelids), axillae, umbilicus, upper chest, and vulva.
 - d. Most often multiple, skin-colored or yellow firm papules occurring in primarily in pubertal women.
 - e. Treatment: Electrosurgery.
- 7. Lipoma
 - a. Single or multiple benign fatty tumor(s)
 - b. Neck and trunk common sites.
 - c. Clinically manifest as soft, mobile, almost fluctuant masses that are not adherent to the skin
 - d. Treatment: Surgical excision (esp. > 5cm).
- 8. Verruca (wart)
 - a. Usual viral etiology (i.e., HPV).
 - b. May disappear spontaneously or respond to medical treatment.
 - c. Do not excise as recurrence is likely; use cautery or liquid nitrogen.
 - d. Do use pulsed dye laser for recalcitrant warts
- 9. Miscellaneous
 - a. Pyogenic granuloma
 - i. Ulcerating, tumor-like growth of granulation tissue, the result of chronic infection, may resemble malignant tumor
 - ii. Treat by topical silver nitrate, excision, curettage, laser
 - b. Xanthoma (xanthelasma)
 - i. Small deposits of lipid-laden histiocytes, most common in eyelids, sometimes associated with systemic disorders (hyperlipidemia, diabetes)
 - ii. Treat by excision
 - c. Rhinophyma
 - i. Severe acne rosacea of the nose, overgrowth of sebaceous glands causing bulbous nose
 - ii. Treat by surgical planing (shaving) with dermabrasion or laser
 - d. Epidermoid (often misnamed sebaceous)
 - i. Almost always attached to overlying skin, frequently acutely inflamed if not excised
 - ii. Excise with fusiform-shaped island of overlying skin attachment (including puncture) when not inflamed
 - iii. Acutely inflamed cyst may require incision and drainage with subsequent excision

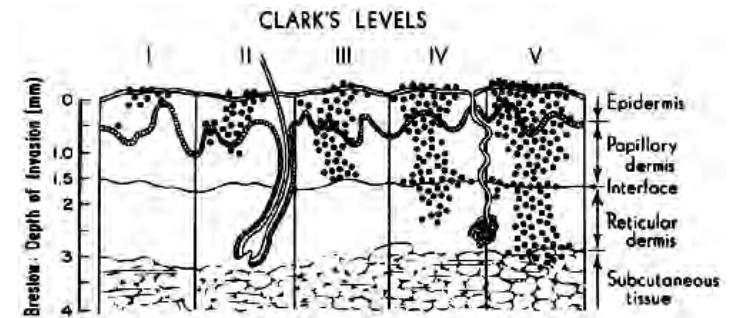
- e. Hidradenitis suppurativa
 - i. A chronic, recurrent inflammatory disease of hair follicles (folliculitis)
 - ii. Occurs in axilla, groin and perineum and breast (intertriginous areas)
 - iii. Treatment
 - (a) In early stages, antibiotics (topical clindamycin or oral minocycline) and local care including incision and drainage of abscesses
 - (b) Later stages require excision of all involved tissue, and primary closure (associated with local recurrence) or closure by secondary intention (preferred method) or skin grafting
- C. Congenital Lesions
 - 1. Dermoid Cyst
 - a. Congenital lesion usually occurring in lines of embryonic fusion (lateral 1/3 of eyebrow, midline nose, under tongue, under chin)
 - b. CT scan of midline dermoid to rule out intracranial extension
 - 2. Nevi
 - a. Classification
 - i. Intradermal (dermal)
 - (a) Most common, usually raised, brown, may have hair
 - (b) Essentially no potential for malignant change to melanoma
 - (c) Treatment: Surgical excision necessary if concerning changes arise, or if lesion is aesthetically displeasing to patient
 - ii. Junctional
 - (a) Flat, smooth, hairless, various shades of brown
 - (b) Nevus cells most likely at basement membrane
 - (c) Low malignant potential
 - (d) Treatment: Surgical excision necessary if concerning changes arise, or if lesion is aesthetically displeasing to patient
 - iii. Compound
 - (a) Often elevated, smooth or finely nodular, may have hair
 - (b) Low malignant potential
 - (c) Treatment: Surgical excision necessary if concerning changes arise, or if lesion is aesthetically displeasing to patient
 - iv. Large pigmented (bathing trunk nevus)
 - (a) Congenital lesion commonly occurring in dermatome distribution
 - (b) Defined as a lesion >20 sq. cm in size
 - (c) Potential for malignant transformations (2-32% lifetime risk reported in literature)
 - (d) Treatment: Surgical excision usually indicated. Due to large surface area, tissue expanders are required to recruit locoregional, unaffected skin via expanded flap transposition. Alternatives include skin grafting, laser resurfacing, or staged excision. It should be noted, however, with laser treatment only part of the nevus cells are ablated, which leads to destruction of local architecture. This may subvert clinical monitoring and pathologic analysis of tissue biopsies.
 - v. Dysplastic nevus
 - (a) Irregular border

- (b) Variegated in color
 - (c) Often familial
 - (d) Most likely nevus to become malignant melanoma
 - (e) Treatment: Surgical excision
 - vi. Nevus sebaceous
 - (a) Most often seen on scalp and face
 - (b) 15-20% incidence of basal cell carcinoma
 - (c) carcinoma
 - (d) Yellowish orange, salmon-colored, greasy elevated plaque
 - (e) Treatment: Surgical excision. This can either be performed in infancy/early childhood or adolescence, as the incidence of malignancy rises after puberty.
 - b. Summary: Treatment of Congenital Nevi
 - i. Excision and histological examination of all suspicious pigmented lesions based on:
 - (a) Clinical appearance
 - (b) History of recent change in:
 - (i) Surface area (enlarging)
 - (i) Elevation (raised, palpable, nodular, thickened)
 - (i) Color (especially brown to black)
 - (i) Surface characteristics (scaly, serous discharge, bleeding and ulceration)
 - (i) Sensation (itching or tingling)
 - ii. Excision of unsightly or constantly irritated nevus (beltline, under bra or beard area)
 - iii. Careful follow-up of very large pigmented nevus, with excision of any area of change (nodularity) or staged excision of as much lesion as possible (tissue expanders and primary closure, or skin grafts when necessary)
3. Vascular Lesions — Most common benign tumor of infancy
- a. Hemangioma
 - i. Hemangioma (a.k.a, strawberry nevi)
 - (a) Most common benign vascular tumor, appearing at or shortly after birth
 - (b) Three clinical phases evident: proliferative (tumor increases in size for up to 6-7 months), involutinal (stops growing, becomes gray/white in areas and then begins to regress over several or more years), and fibrotic.
 - (c) Treatment: Need for treatment rare, and depends on anatomical site and symptoms (see below). Observe frequently at first and reassure parents
 - (d) Indications for treatment: Obstructive symptoms (airway, visual), or bleeding. Systemic therapy (corticosteroids, 2mg/kg) is first line option; laser therapy may be indicated early. Interferon may be indicated for uncontrolled lesions. Surgery may eventually be indicated for removal of any disfiguring fibrofatty remnant, or in situations when bleeding is refractory to conservative measures.
 - b. Malformations
 - i. Capillary malformations (port-wine stain)

- (a) Pink-red-purple stain in skin, usually flat, but may be elevated above skin surface. Does not regress
 - (b) Treatment: Laser therapy best (flashlamp-pumped, pulsed dye laser, 585nm); multiple (>3) laser sessions may be necessary; surgical excision not indicated
 - ii. Arterio-venous malformation
 - (a) Large blood-filled venous sinuses beneath skin and mucous membranes. Low flow. No bruit
 - (b) Treatment: Angiography for larger and progressive lesions. Embolization with (2-3 days prior to) surgery is beneficial. Excision may be indicated
 - iii. Arterio-venous
 - (a) Progressive increase in size and extent, multiple arteriovenous fistulas, bruit
 - (b) A-V shunts or angiography
 - (c) Treatment is embolization under angiographic control by itself or prior to surgical excision
 - iv. Lymphatic
 - (a) Subcutaneous cystic tumor (cystic hygroma) of dilated vessels which can be massive and disfiguring
 - (b) May cause respiratory obstruction, may become infected
 - (c) Spontaneous regression can occur, but surgical excision is often indicated
 - (d) Lymphatic malformation can occur with arteriovenous malformation
 - v. Mixed
- D. Premalignant and Malignant Lesions of the Skin and Subcutaneous Tissue
1. Actinic or Senile Keratosis
 - a. Crusted, inflamed, history of exposed areas of face and scalp, chronic sun exposure or history of x-irradiation
 - b. Premalignant, biopsy of suspicious lesions, especially when nodular (excision), liquid nitrogen, topical chemotherapy (5-fluorouracil)
 2. Squamous cell carcinoma in situ (Bowen's Disease)
 - a. Scaly brown, tan or pink patch
 - b. Frequently associated with chronic arsenic medication
 - c. May be associated with internal malignancy
 - d. May develop into invasive squamous carcinoma
 - e. Treat by excision
 3. Squamous cell carcinoma
 - a. Rapidly growing (months) nodular or ulcerated lesion with usually distinct borders
 - b. Occurs on exposed areas of body and x-irradiated areas and in chronic non-healing wounds (Marjolin's ulcer). Can metastasize to regional lymph nodes (10%)
 - c. Treatment is surgical excision with adequate margins or with histologic frozen section or with Moh's micrographic surgery followed by reconstruction
 4. Basal cell carcinoma
 - a. Most common skin cancer
 - b. Types — all types may show ulceration, with rolled smooth pearly borders

- i. Nodular — well-defined “rodent ulcer”
 - ii. Superficial
 - iii. Pigmented — resembles melanoma
 - iv. Morphea Type — sclerosing — poorly defined borders, high recurrence rates
 - c. Usually seen on face or other sun-exposed areas of body, caused by UVB ultraviolet radiation
 - d. Slow-growing (years), destroys by local invasion, particularly hazardous around eyes, ears, nose
 - e. Very rarely metastasizes
 - f. Treatment: Surgical excision with adequate margins or with frozen section or with Mohs micrographic surgical excision followed by reconstruction
5. Melanoma
- a. Cause of great majority of skin cancer deaths
 - b. Early lymph node and systemic blood-borne metastases — frequently considered a systemic disease
 - c. Usually appears as black, slightly raised, nonulcerative lesion arising de novo or from a preexisting nevus
 - d. Early recognition of changes in color, size or consistency of a pigmented nevus is critical (ABCD's = asymmetry, irregular borders, variegated color, diameter > 6mm).
 - e. Classification
 - i. Pre-malignant: Lentigo maligna (Hutchinson's freckle)
 - (a) Flat, varied shades of brown pigmentation, larger than most nevi, irregular borders, smooth
 - (b) Usually slow-growing, most often on face, more frequently in elderly
 - (c) High incidence of development of invasive melanoma
 - (d) Treat by excision, with graft or flap reconstruction if necessary
 - ii. Invasive
 - (a) Lentigo maligna melanoma (10%)
 - (i) Develops in a Hutchinson's Freckle, usually as a thickened, elevated nodule
 - (b) Superficial spreading melanoma (70%)
 - (i) Flat to slightly elevated, may have a great variety of colors
 - (i) Lesion initially spreads horizontally
 - (c) Nodular melanoma (15%)
 - (i) Characteristically blue/black in color
 - (i) May be unpigmented (amelanotic)
 - (i) Grows vertically, often with early surface ulceration
 - (d) Acral lentiginous melanoma (5%)
 - (i) On mucous membranes, palms, soles and subungual
 - (i) May be amelanotic in African-Americans
 - f. Histologic staging and correlation with metastases
 - i. Breslow's depth of invasion — more reliable indicator of prognosis than Clark's level (Fig. 3-1)
 - (a) Less than 0.76 mm — metastases virtually 0%
 - (b) 1.50-3.99 mm — metastases 50%

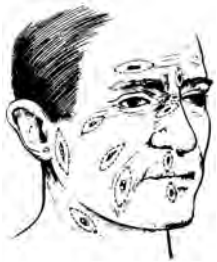- (c) Greater than 4 mm — metastases 66%
- ii. Clark's levels of cutaneous invasion (Fig. 3-1)
 - (a) Level I (in situ) above the basement membrane — node metastases extremely rare
 - (b) Level II — in the papillary dermis — metastases in 2-5%
 - (c) Level III — to the junction of papillary and reticular dermis — metastases in up to 20%
 - (d) Level IV — into the reticular dermis — metastases in 40%
 - (e) Level V — into the subcutaneous tissue — metastases in 70%



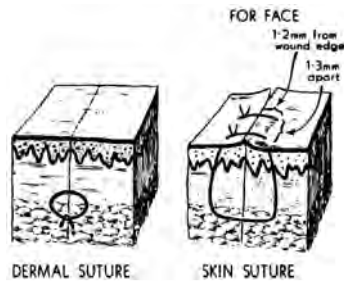
(FIGURE 3-1)

- iii. Staging
 - (a) Stage I: lesions less than 2 mm thick without ulceration
 - (b) Stage II: 1-2 mm thick with ulceration or greater than 2 mm thick with or without ulceration
 - (c) Stage III: regional node metastasis
 - (d) Stage IV: distant metastasis
- g. Treatment
 - i. Most important is the manner in which the primary lesion is removed
 - ii. Complete excisional biopsy is necessary to determine level and thickness
 - iii. Treated by “wide” excision with primary closure, split-thickness skin graft, or flap closure. Please note that permanent sections are often required to determine clear margins, and that frozen sections may not be reliable for this purpose.
 - (a) Thin lesions (less than 1 mm) = 1 cm margin
 - (b) Thick lesions (greater than 1 mm) = 2 cm margin
 - (c) Note that margin also depends on location and may be compromised in critical areas
 - iv. Sentinel node biopsy is used to determine regional metastases. Generally indicated for intermediate thickness lesions.

- v. Regional node dissection indicated for positive sentinel nodes
 - vi. Node dissection performed for palpable nodes
 - vii. Extremity perfusion may be helpful for selected cases
 - viii. Radiotherapy, chemotherapy, and immunotherapy (i.e. Interferon) have not been proven curative but may have some palliative effect
6. Dermatofibrosarcoma protuberans (DFSP)
- a. Rare tumor
 - b. Frequently occurs in head and neck, and genitalia (vulvar) regions.
 - c. Treatment: Chemo- and radioresistant tumor. Requires wide excision to avoid recurrence (3-6cm). High recurrence rate in cases where wide local excision <3cm. Moh's surgery can also be indicated for these tumors.



(FIGURE 3-2)



(FIGURE 3-3)

CHAPTER 3 — BIBLIOGRAPHY

SKIN AND SUBCUTANEOUS LESIONS

1. Fitzpatrick T.B., Johnson R.A., Wolff K., Palano M. K., Suurmond D. Color Atlas and Synopsis of Clinical Dermatology: Common and Serious Diseases. 3rd ed. McGraw-Hill, New York. 1997.
2. Niessen F. B., Spauwen P.H.M., Schalkwijk J., Kon M. On the nature of hypertrophic scars and keloids: A review. *Plast. Reconstr. Surg.* 1999; 104: 1435-1458.
3. Cruse, C.W. and D. Reintgen: Treatment of primary malignant melanoma: A Review. *Sem Surg Onc.*, 1993; 9:215-218.
4. Eshima, I. Role of plastic surgery in the treatment of malignant melanoma. *Surg Clin North Amer.* 1996; 26:1331-1342.
5. Goldberg, D.P. Assessment and surgical treatment of basal cell skin cancer. *Clin Plast Surg.* 1997; 24:673-86.
6. Kogan, L. et al. Metastatic spinal basal cell carcinoma: a case report and literature review. *Ann Plast Surg.* 2000; 44:86-8.
7. Morganroth, G.S. and D.J. Leffell "Non-Excisional Treatment of Benign and Premalignant Cutaneous Lesions." *Clin Plast Surg.* 1993; 20:91-104.
8. Thompson, H.G. "Common Benign Pediatric Cutaneous Tumors: Timing and Treatment." *Clin Plast Surg.*, Jan 1990; 17:49-64.

CHAPTER 4

HEAD AND NECK

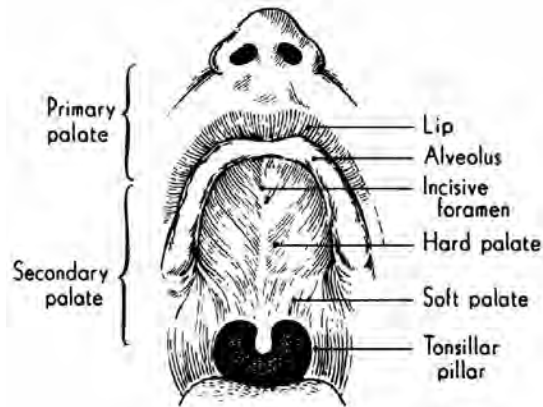
Problems of the head and neck in the practice of plastic surgery include congenital, traumatic, infectious, neoplastic, and other conditions. A working knowledge of embryology and anatomy of the head and neck is crucial in the diagnosis and surgical treatment of these diseases.

I. CONGENITAL

A. Cleft Lip and Cleft Palate

1. Anatomy (Fig. 4-1)

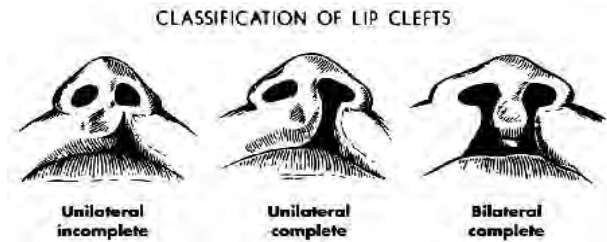
- a. Cleft Lip: occurs anterior to the incisive foramen and may also involve the alveolar process
- b. Cleft Palate:
 - i. Primary cleft palate: failure of fusion of median and lateral palatine processes
 - ii. Secondary cleft palate: failure of fusion of lateral palatine processes
- c. Submucous cleft palate (SMCP):
 - i. occult cleft of the soft palate
 - ii. classic clinical triad:
 - (a) bifid uvula
 - (b) notching of the hard palate
 - (c) zona pellucida – thinned area of soft palate containing only mucosa due to levator veli palatini muscles inserting on hard palate



(FIGURE 4-1)

2. Classification

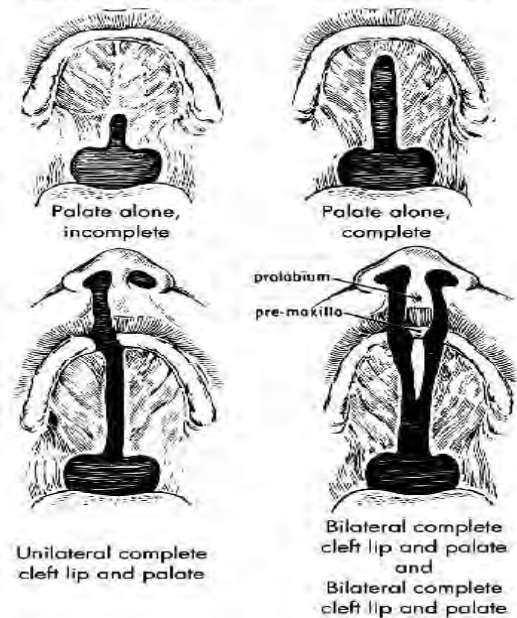
- a. Cleft Lip (Fig. 4-2)
 - i. Unilateral
 - (a) Complete
 - (b) Incomplete
 - ii. Bilateral
 - (a) Complete
 - (b) Incomplete



(FIGURE 4-2)

- b. Palate (Fig. 4-3)
 - i. Palate alone
 - (a) Incomplete
 - (b) Complete
 - ii. Complete cleft palate
 - (a) Unilateral
 - (b) Bilateral

CLASSIFICATION OF PALATE CLEFTS



(FIGURE 4-3)

- 3. Prevalence of Unilateral Clefts
 - a. Cleft lip with or without cleft palate (CL±CP)
 - b. Ethnicity/Sex
 - i. 1:1000 Caucasians
 - ii. 1:2000 African-Americans
 - iii. 1:500 Asians
 - iv. 2:1 males:females
 - c. Cleft of palate alone (CP)
 - i. 1:2000 (all ethnicity)
 - ii. 1:2 males:females
- 4. Occurrence risk in offspring (Table 4-1)

Affected Relatives	Predicted Outcomes*
<i>CL±CP</i>	
One sibling	= 4%
One Parent	= 4%
Sibling and a Parent	= 16%
<i>CP</i>	
One Sibling	= 2.4%
One Parent	= 2.4%
Sibling and a Parent	= 15%

Note — If congenital lip pits, inherited as autosomal dominant gene with variable penetrance (Van der Woude's Syndrome) — 50% incidence

**General predictions; individual cases may vary*

Table 4-1

- 5. Etiology
 - a. Multifactorial combination of heredity with or without environmental factors
 - b. Teratogenic agents — e.g. phenytoin, alcohol
 - c. Nutritional factors may contribute — folate deficiency
 - d. 3% of CL±CP are syndromic
- 6. Embryology
 - a. Cleft lip with palate forms at 4-6 weeks due to lack of mesenchymal penetration (merging) and fusion
 - b. Isolated cleft palate forms later, at 7-12 weeks, from lack of fusion
- 7. Pathophysiology and Functional Deficits
 - a. Cleft lip
 - i. Inability to form fluid and air seal in eating or speech
 - ii. Malocclusion as a result of intrinsic deformities of alveolar process and teeth
 - iii. Lack of continuity of skin, muscle and mucous membrane of lip with associated nasal deformity and nasal obstruction
 - iv. Deformity

- b. Cleft palate
 - i. Inability to separate nasal from oral cavity so that air and sound escape through nose in attempted speech
 - ii. Feeding impaired by loss of sucking due to inability to create intra-oral negative pressure
 - iii. Loss of liquids and soft foods through nose due to common nasal-oral chamber
 - iv. Middle ear disease and chronic otitis media due to Eustachian tube dysfunction
 - v. May be associated with Pierre-Robin sequence (cleft palate, micrognathia, glossoptosis). In these cases, airway obstruction and failure to thrive may be present. These cases may require ICU monitoring, prone positioning, nasopharyngeal airway, tongue-lip adhesion, tracheostomy, and now mandibular distraction (moving the base of the tongue forward by mandibular advancement). Distraction has been used with some good effect in severe cases, avoiding tracheostomy.
- 8. Team concept

Because of multiple problems with speech, dentition, hearing, etc., management of the patient with a cleft should be by an interdisciplinary team, preferably in a cleft palate or craniofacial center. Team members include: plastic surgeon, orthodontist, dentist, geneticist, pediatrician, speech therapist, audiologist, social worker, and psychologist.
- 9. Timing of Surgical Intervention
 - a. Cleft lip
 - i. Most common 10 weeks of age.
 - ii. Once followed "rule of 10's" (10 weeks of age, Hgb 10, 10 lbs.), but now this rule is more historical.
 - iii. Range of cleft lip repair varies from 0-3 months of age in full-term, otherwise healthy, infant.
 - b. Cleft palate
 - i. Before purposeful sounds made (9-12 mos)
 - ii. depending upon health of infant, extent of cleft, but certainly before 18 months of age, if possible
 - c. Cleft nasal deformity
 - i. Most centers perform primary correction at the time of lip repair
 - ii. Secondary rhinoplasty at preschool age (4-5 years)
 - d. Alveolar cleft
 - i. Most centers perform secondary bone grafting at the stage of mixed dentition (9-12 years of age), just before eruption of the permanent canine, which is often affected by the cleft.
 - e. Dentofacial skeletal abnormality
 - i. In most cleft patients, this manifests as maxillary retrusion/hypoplasia
 - ii. In 25% of cleft patients, orthognathic surgery (jaw-straightening procedure) has to be performed to correct a malocclusion (abnormal bite).
 - iii. Orthognathic surgery can only be performed in skeletally mature individuals (14-16 years of age, women; 17-19 years of age, men).

- iv. With the advent of craniofacial distraction, surgical intervention can be performed earlier, but both patient and parents must be advised that the growing child may "outgrow" the correction, necessitating a repeat procedure.
- 10. Principles of Repair
 - a. Cleft lip (3 months)
 - i. Repair of skin, muscle and mucous membrane to restore complete continuity of lip, symmetrical length and function
 - ii. Simultaneous repair of both sides of a bilateral cleft lip
 - iii. Preference for primary nasal reconstruction at time of lip repair
 - iv. In wide clefts (>10mm), presurgical orthodontics (palatal appliance, nasoalveolar molding) may be indicated, or a cleft lip adhesion (surgery to initially bring lip segments together, followed by definitive repair of lip 3 months later).
 - b. Cleft palate (9-12 months)
 - i. One stage repair of both hard and soft palate
 - c. Alveolar cleft (6-12 years)
 - i. At the time of eruption of permanent canine teeth
- 11. Secondary Repair
 - a. Cleft lip
 - i. Orthognathic Lefort I osteotomy for maxillary hypoplasia (16 years)
 - ii. Secondary rhinoplasty (16-18 years)
 - b. Cleft palate (4-6 years)
 - i. Correction of velopharyngeal inadequacy (nasal escape air due to remaining palatal defect): 4-6 years of age
 - ii. Repair of any oronasal palatal fistula
- B. Other Congenital Anomalies
 - 1. Craniosynostosis
 - a. Definition: Premature fusion of one or more cranial vault sutures.
 - b. 343 out of 1,000,000 live births
 - c. Categorized into syndromic and nonsyndromic types.
 - d. Nonsyndromic craniosynostosis:
 - i. Order of frequency according to suture type:
 - (a) Sagittal
 - (b) Metopic
 - (c) Coronal
 - (d) Lambdoid
 - ii. Characteristic head shape according to suture affected:
 - (a) Sagittal - scaphocephaly (scapho, Gr., meaning boat-shaped)
 - (b) Metopic - trigonocephaly (trigono, Gr., meaning triangular- or keel-shaped forehead)
 - (c) Coronal - brachycephaly (brachy, Gr., meaning short in AP direction).
 - iii. Ongoing debate as to whether or not these patients have an increased incidence of developmental delay
 - iv. Treatment:
 - (a) anterior vault reshaping (fronto-orbital advancement/reshaping)
 - (b) total vault reshaping

- (c) posterior vault reshaping
- (d) depending on location and severity of craniosynostosis.
- (e) Usually performed within first year of life to take advantage of molding capacity of skull
- e. Syndromic:
 - i. Major associated syndromes:
 - (a) Apert (craniosynostosis, exorbitism, midfacial retrusion with complex syndactyly of the 2-4 digits of the hands/feet)
 - (b) Crouzon (craniosynostosis, exorbitism, midfacial retrusion)
 - (c) Pfeiffer (craniosynostosis, exorbitism, midfacial retrusion, broad thumbs and toes)
 - ii. Characteristic head shape involves turribrachycephaly (turri-, Gr., tower)
 - iii. 50% of Apert syndrome patients have substantial mental delay; Crouzon and Pfeiffer syndrome patients usually develop normally
 - iv. Genetic defect identified in fibroblast growth factor receptor (FGFR) genes (Apert, Crouzon---FGFR2, Pfeiffer---FGFR1)
 - v. Goals of surgery:
 - (a) Release fused cranial sutures
 - (b) correct profound exorbitism to prevent corneal exposure/blindness
 - (c) correct malocclusions
 - vi. Surgical interventions:
 - (a) Anterior/posterior/total vault reshaping (0-1 years)
 - (b) Monobloc (osteotomy and advance forehead and face simultaneously with bone grafts/fixation)
 - (c) Le Fort III (osteotomy and advance face) (4-6 years)
 - (d) Craniofacial distraction leads to greater advancement, less relapse than conventional procedures.
- 2. Facial Dysostoses
 - a. Treacher-Collins Syndrome (Mandibulofacial Dysostosis)
 - i. Rare, autosomal dominant, variable penetrance disorder
 - ii. Affected gene on chromosome 5q
 - iii. Clinical manifestations:
 - (a) hypoplasia/aplasia of the zygomatic bone
 - (i) lateral orbit deficiency
 - (ii) midface retrusion
 - (iii)lateral canthus hypoplasia/downward slanting palpebral fissures
 - (b) colobomas
 - (c) variable external ear malformations and deafness
 - (d) mandibular hypoplasia with microretrognathia
 - (i) airway compromise
 - (ii) necessitates tracheostomy and distraction of mandible
 - (e) choanal atresia
 - (f) bilateral cleft palate
 - (g) normal intelligence
 - iv. Treatment:

- (a) Skeletal and soft tissue augmentation of deficient areas with autogenous bone (calvarium, rib, iliac crest) and autologous fat/tissue transfer, respectively.
- (b) Mandibular distraction may be necessary for achieving a stable airway
- b. Hemifacial Microsomia
 - i. Third-most common congenital malformation (following club foot and cleft lip and palate).
 - ii. 1:7000 live births affected
 - iii. No genetic defect ascribed; leading theory of cause is related to stapedia artery thrombosis during embryogenesis
 - (a) 1st & 2nd branchial arches affected
 - iv. Usually associated with microtia
 - v. Manifestations:
 - (a) hemifacial deficiency (skeletal and soft tissue)
 - (i) C-shape deformity
 - (ii) off center position of chin
 - (b) microtia
 - (c) mandibular hypoplasia
 - (i) malocclusion from an abnormal cant (secondary to reduced vertical height of the ramus)
 - (d) macrostomia
 - (e) hearing loss
 - vi. Associated with Tessier #7 facial cleft and variable facial nerve palsy
 - vii. Pruzansky classification for mandibular discrepancy classification (OMENS):
 - (a) Orbit
 - (b) Mandible
 - (c) Ear
 - (d) Nerve
 - (e) Soft tissue
 - viii. Treatment:
 - (a) Augment deficient areas
 - (i) Skeletal: autogenous bone (calvarium, rib, iliac crest)
 - (ii) Soft tissue: free flap and/or fat grafting
 - (b) Mandibular depends upon severity of hypoplasia. Distraction may be necessary for achieving correction of malocclusion versus conventional orthognathic procedures to correct jaw discrepancies in adolescence.
 - (c) bone-anchored hearing aids
- c. Goldenhar Syndrome
 - i. Also known as oculoauriculo-vertebral (OAV) spectrum
 - ii. Manifestations:
 - (a) hemifacial microsomia,
 - (b) vertebral spine abnormalities
 - (c) abnormalities of heart, kidneys, lungs
- 3. Embryologic Defects
 - a. Branchial cyst, sinus, or fistula

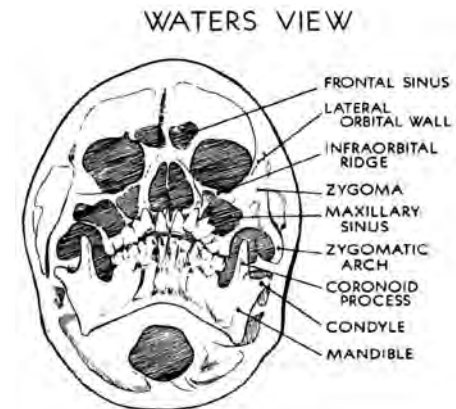
- i. Epithelial-lined tract frequently in the lateral neck presenting along the anterior border of the sternocleidomastoid muscle.
- ii. May present as a cyst or as a sinus connected with either the skin or oropharynx, or as a fistula between both skin and oropharynx openings
- iii. Treatment — excision
- b. Thyroglossal duct cyst or sinus
 - i. Cyst in the mid-anterior neck over or just below the hyoid bone, with or without a sinus tract to the base of the tongue (foramen cecum)
 - ii. Treatment — excision
- c. Ear deformities
 - i. Complete absence (anotia) — very rare
 - ii. Vestigial remnants or absence of part of ear (microtia)
 - iii. Absence of part or all of external ear with mandibular deformity (hemifacial microsomia)
 - iv. Abnormalities of position (prominent ears)
 - v. Treatment:
 - (a) Anotia or microtia—construction from autogenous cartilage graft or synthetic implant, vascularized fascial flap, skin graft — usually requires more than one operation. (Traumatic loss of part or all of ear is treated similarly).
 - (b) Use of a prosthetic ear may be indicated in some patients
 - (c) Prominent ears — creation of an antihelical fold and/or re-positioning/reduction of concha

II. TRAUMATIC

- A. Facial soft tissue injuries
 - 1. Stabilize patient and manage concomitant traumatic injuries (ABCDE, primary survey)
 - 2. Establish airway (may be obstructed by blood clots or damaged parts)
 - a. Finger (jaw thrust, e.g.)
 - b. Suction
 - c. Endotracheal intubation
 - d. Cricothyroidotomy or tracheotomy
 - 3. Control of active bleeding by pressure until control by directly ligating in operating room or embolization in interventional radiology suite
 - 4. Palpate facial skeleton for underlying bone injury; rule out injury to facial nerve, parotid duct, etc.
 - 5. Radiologic evaluation (C-spine X-rays, CT scan, panorex)
 - 6. Tetanus and antibiotic prophylaxis
 - 7. Repair as soon as patient's general condition allows with
 - a. Preferably less than 8 hours post-injury
 - b. Primary closure may be delayed up to 24 hours
 - c. Conservative debridement of nonviable tissue and foreign bodies
 - d. Careful wound irrigation with physiologic solution
 - e. Meticulous re-approximation of anatomy

B. Facial bone fractures

- 1. Diagnoses
 - a. Consider patient history
 - b. Physical examination for asymmetry, bone mobility, diplopia, extraocular muscle entrapment, sensory loss, malocclusion, local pain
 - c. Old (pre-injury) photographs often useful to assess baseline
 - d. Imaging
 - i. Skull x-ray (rarely performed today) and cervical spine
 - (a) Waters view for facial bones (Fig. 4-6); good for orbital floor

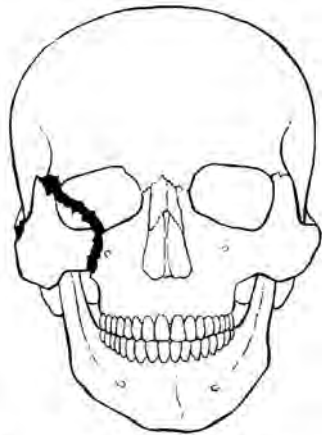


(FIGURE 4-6)

- ii. CT scan (now imaging modality of choice)
- iii. C-spine x-ray
- iv. Panorex x-ray if mandible fracture present and C-spine cleared
- 2. Treatment
 - a. Re-establishment of normal occlusion is of primary importance
 - b. Use of interdental wiring (mandibulomaxillary fixation/MMF), plating, or other devices in patient with teeth
 - c. Use of patient's dentures or fabricated temporary dentures in edentulous patient
 - d. Reduction and immobilization of other fractures
 - e. When dealing with panfacial fracture, stabilize articulating element (mandible), first by mandibulomaxillary fixation (MMF)
 - f. Once occlusion is aligned, work systematically, either "outside-in" (Gruss) or "inside-out" (Manson), establishing facial height, width, and projection by aligning key facial buttresses (open reduction) and plating of fractures (internal fixation)

3. Specific Fractures

- a. Mandible — often bilateral (ring concept)
 - i. Depending on anatomical region (parasymphysis, body, angle, subcondyle) and overall function (malocclusion), open reduction and internal fixation (ORIF) may be indicated.
 - ii. Clinical signs:
 - (a) Malocclusion
 - (b) Sensation of chin decreased due to mental nerve injury
 - iii. Imaging
 - (a) Panorex x-ray
 - (b) CT scan
 - (c) C-spine x-ray: 10-13% of mandible fractures coincide with c-spine fracture; maintain C-spine stabilization until absence of injury can be confirmed
- b. Zygomatic complex (Fig. 4-4)

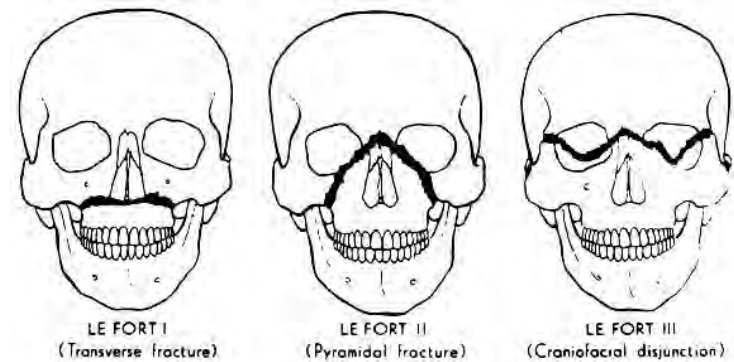


FRACTURE OF ZYGOMATIC COMPLEX

(FIGURE 4-4)

- i. Commonly associated with orbital floor fractures
 - (a) Eye exam
 - (i) Extraocular movements / entrapment
 - (ii) Visual acuity

- (iii)Globe injury
 - (b) Ophthalmology consultation if suspicious of globe injury
- ii. Superior orbital fissure syndrome
 - (a) Due to injury to contents of superior orbital fissure (CN III, IV, VI)
 - (b) Ophthalmoplegia (CN III, IV, VI)
 - (c) Proptosis
 - (d) Ptosis (CN III)
 - (e) Dilated pupil (CN III)
 - (f) If also blindness (CN II), called ORBITAL APEX SYNDROME (surgery urgent)
- iii. Indications for surgery
 - (a) Entrapment
 - (b) Enophthalmos
 - (i) Severe displacement creating facial asymmetry
- c. Maxilla
 - i. Le Fort fractures (Fig. 4-5)
 - (a) Disrupts vertical maxillary buttresses
 - (i) Zygomaticomaxillary
 - (ii) Nasofrontal / piriform
 - (iii)Zygomaticofrontal
 - (iv)Pterygomaxillary
 - (b) Treatment involves open reduction and internal fixation with miniplates to re-establish facial proportions and occlusion

LE FORT I
(Transverse fracture)LE FORT II
(Pyramidal fracture)LE FORT III
(Craniofacial disjunction)

(FIGURE 4-5)

- d. Naso-orbital-ethmoidal (NOE)
- e. Isolated orbital floor fractures: blow-out versus blow-in

- i. Check for entrapment (failure to move eye in all directions)—if present, must decompress orbit within 48 hours
- ii. Check for enophthalmos (position of globe in relation to unaffected globe in worm's eye view).
- iii. Must operate for enophthalmos 2mm or greater.
- f. Frontal sinus
- g. Pediatric craniofacial fractures: Usually more conservative with operative repair in this patient population, due to growing facial skeleton and developing dentition.

III. INFECTIONS

- A. The head and neck are relatively resistant to infection due to their robust vascularity
- B. Routes of spread
 - 1. Upper aerodigestive infections may track into the mediastinum
 - 2. Scalp and orbital infections may spread intracranially via the dural sinuses and ophthalmic veins
- C. Facial cellulitis — mostly due to staph or strep — may use a cephalosporin
- D. Oral cavity infections — mostly due to anaerobic strep and bacteroides. Use extended spectrum penicillin or other anaerobic coverage
- E. Acute Sialadenitis — fever, pain, swelling over the involved parotid gland. Seen with dehydration, debilitation, diabetics, poor oral hygiene. Treat with antibiotics, fluids
- F. Atypical mycobacteria — seen in enlarged lymph nodes; drainage rarely required. Special cultures may be necessary

IV. NEOPLASTIC (exclusive of skin — see Chapter 3)

- A. Salivary gland tumors or disorders
 - 1. Classification of tumors by location
 - a. Parotid — most common (80%), most are benign (80%)
 - b. Submandibular — 55% incidence of malignancy
 - c. Minor salivary glands — least common, with highest incidence of malignancy (about 75%)
 - 2. Diagnosis
 - a. Primarily by physical examination
 - i. Any mass in the pre-auricular region or at the angle of the jaw is a parotid tumor until proven otherwise
 - b. Bimanual palpation — simultaneous intraoral and external palpation
 - c. X-rays occasionally helpful for diagnosis of stone; sialography (injection of contrast material into duct) is rarely if ever indicated
 - d. Signs more commonly seen with malignancy
 - i. Fixed or hard mass
 - ii. Pain
 - iii. Loss or disturbance of facial nerve function
 - iv. Cervical lymph node metastases
 - 3. Treatment

- a. For stone near duct orifice
 - i. Simple removal
- b. For benign tumors (or stones in duct adjacent to gland)
 - i. Surgical removal of gland with sparing of adjacent nerves, e.g. facial nerve with parotid; lingual and hypoglossal nerves with submandibular
- c. For malignant tumors
 - i. Surgical removal of entire gland with sparing of nerve branches that are clearly not involved
 - (a) Radiation therapy if tumor not completely removed
 - (b) Cervical lymph node dissection with tumors prone to metastasize to nodes
- 4. Pathology
 - a. Benign
 - i. Pleomorphic adenoma — (benign mixed) high recurrence rate with local excision
 - ii. Papillary cystadenoma lymphomatosum (Warthin's tumor) — may be bilateral — (10%) male, age 40-70
 - b. Malignant
 - i. Mucoepidermoid
 - ii. Malignant mixed
 - iii. Adenocarcinoma
- B. Tumors of oral cavity
 - 1. Classification
 - a. Anatomical — malignancies behave differently according to anatomic site and prognosis worsens from anterior to posterior
 - i. Lip
 - ii. Anterior two-thirds tongue
 - iii. Floor of mouth
 - iv. Buccal
 - v. Alveolar ridge
 - vi. Posterior tongue
 - vii. Tonsillar fossa and posterior pharynx
 - viii. Hypopharynx
 - b. Histopathologic
 - i. Benign — according to site — fibroma, osteoma, lipoma, cyst, etc.
 - ii. Malignant
 - (a) Most are squamous cell carcinoma or variants
 - (b) Palate carcinomas are often of minor salivary gland origin
 - (c) Sarcomas in mandible, tongue, other sites are rare
 - (d) TNM staging is helpful for treatment planning and prognosis (i.e. tumor size, lymph node metastases, systemic metastases)
 - 2. Diagnosis
 - a. Examination — including indirect laryngoscopy and nasopharyngeal endoscopy when indicated
 - b. Biopsy of any lesion unhealed in 2-4 weeks
 - c. X-rays and scans as indicated
 - i. Conventional views, panorex, etc.

- ii. Tomography
- iii. Computerized axial tomography
- iv. Bone scan
- v. Magnetic resonance imaging
- 3. Treatment
 - a. Surgical
 - i. Benign
 - (a) Simple excision
 - ii. Malignant
 - (a) Wide local excision with tumor-free margins
 - (b) Regional lymph node dissection when indicated
 - (c) Palliative resection may be indicated for comfort and hygiene
 - (d) Immediate reconstruction with vascularized flaps when indicated by size and location of defect
 - b. Radiation therapy
 - i. Preoperative
 - (a) To increase chance for cure, especially with large lesions
 - (b) May make an inoperable lesion operable
 - ii. Postoperative
 - (a) If tumor-free margin is questionable
 - (b) For recurrence
 - (c) Prophylactic — controversial
 - c. Chemotherapy — usually for advanced disease

V. MISCELLANEOUS

A. Disorders of the jaw

- 1. Deformities of the mandible
 - a. Classification
 - i. Retrognathia — mandibular retrusion with respect to maxilla
 - ii. Prognathia — mandibular protrusion with respect to maxilla
 - iii. Micrognathia — underdeveloped, retruded mandible
 - iv. Open bite — teeth cannot be brought into opposition
 - v. Crossbite — lower teeth lateral to upper teeth
 - vi. Micro — and macrogenia — under- or overdevelopment of chin
 - b. Diagnosis
 - i. Physical examination
 - ii. X-rays, including a cephalogram (lateral x-ray at a fixed distance) to measure relationships of skull, maxilla and mandible
 - iii. Dental casts are made (usually by an orthodontist) and “model” or mock surgery is performed on the casts to determine degree of advancement/setback of bone.
 - c. Treatment
 - i. Establishment of normal or near normal occlusion of primary importance
 - ii. Use of osteostomies with repositioning of bone segments, bone grafts as needed, with or without orthodontic corrective measures as needed
 - iii. Mandibular distraction for severe discrepancies

- 2. Deformities of the maxilla
 - a. Most commonly, retrusions or underdevelopment, “dish-face”
 - b. Must also examine the vertical height of the midface (vertical maxillary excess, VME versus vertical maxillary deficiency, VMD)
 - c. Diagnosis — as for lower jaw
 - d. Treatment — as for lower jaw
- 3. Temporomandibular joint disorder
 - a. Etiology
 - i. Previous trauma
 - ii. Arthritis
 - iii. Bone overgrowth
 - iv. Bruxism
 - v. Tumors
 - b. Symptoms:
 - i. Pain
 - ii. Crepitus
 - iii. Joint Noises
 - iv. Limited opening
 - v. Occlusion change
 - c. Diagnosis
 - i. Consider patient history
 - ii. Examination
 - (a) Auscultation
 - (b) Opening
 - (c) Occlusion
 - iii. X-rays
 - (a) Tomograms
 - (b) Arthrogram/arthroscopy
 - (c) MRI
 - d. Treatment
 - i. Conservative: joint rest, analgesics, bite plate, etc.
 - ii. Surgery — seldom indicated
- B. Facial paralysis

Loss of facial nerve results in very significant asymmetry and deformity of the face, drooling, exposure of the cornea on the affected side. Deformity is accentuated by muscle activity of normal side (if unilateral)

 - 1. Etiology
 - a. Idiopathic (Bell’s palsy)
 - b. Congenital
 - c. Traumatic
 - d. Infectious
 - e. Tumor
 - f. Vascular (intracranial)
 - 2. Diagnosis
 - a. Demonstrated by asking patient to raise eyebrow, smile, etc.

3. Treatment includes:
 - a. Supportive — for most Bell's palsies
 - b. Protect cornea by taping lids, lid adhesions—ophthalmology consultation is critical
 - c. Re-establishment of nerve function by repair or nerve graft (sural nerve common donor nerve)
 - d. Other measures, such as muscle transfers, static suspension, skin resections, free tissue transfers of muscle, etc.

CHAPTER 4 — BIBLIOGRAPHY

HEAD AND NECK

1. Sperber GH. Craniofacial Development. B.C. Decker Inc., Hamilton, 2001.
2. Cohen MM: Etiology and pathogenesis of orofacial clefting. *Oral Maxillofac. Surg. Clin. No. Amer.* 2000; 12: 379-397.
3. Evans, G.R. and Manson, P.N. Review and current perspectives of cutaneous malignant melanoma. *J Am Coll Surg.* 1994;178:523-40.
4. Gruss, J.S. Advances in craniofacial fracture repair. *Scand J Plast Reconstr Surg Hand Surg Suppl.* 1995; 27:67-81.
5. Manson PN, Hoopes, JE, Su CT. Structural pillars of the facial skeleton: An approach to the management of Le Fort fractures. *Plast. Reconstr. Surg.* 1980; 66(1): 54-61.
6. Luce, E.A. Reconstruction of the lower lip. *Clin Plast Surg.* 1995; 22:109-21.
7. Manson, P.N. et al. Subunit principles in midline fractures: the importance of sagittal buttresses, soft-tissue reductions, and sequencing treatment of segmental fractures. *Plast Reconstr Surg.* 1998; 102:1821-34.
8. Wells, M.D. et al. Intraoral reconstructive techniques. *Clin Plast Surg.* 1995; 22:91-108.
9. Williams, J.K. et al. State-of-the-art in craniofacial surgery: nonsyndromic craniosynostosis. *Cleft Palate Craniofac J.* 1999; 36:471-85.

CHAPTER 5

BREAST, TRUNK AND EXTERNAL GENITALIA

Reconstructive challenges of the breast, trunk and genitalia focus first on restoring structural and functional integrity. Restoration of the normal body contours of both male and female anatomy also deserves consideration.

I. BREAST

A. Breast Anatomy:

1. Breast:
 - a. Glandular and adipose tissue enclosed by superficial fascial system and deep fascia overlying chest wall muscles
 - b. Cooper's ligaments: suspensory attachment of the breast to the overlying fascia anteriorly
 - c. Boundaries:
 - i. Level of 2nd to 6th rib anteriorly
 - ii. Superior border is clavicle, inferior border is rectus abdominis fascia
 - iii. Medial border is sternum, lateral border is anterior border of latissimus dorsi muscle
1. Vasculature:
 - a. Internal mammary artery perforators (60%)
 - b. Lateral thoracic artery (30%)
 - c. Thoracoacromial artery: pectoral branches supply pectoralis major muscle and overlying breast tissue
 - d. Intercostal arteries 3, 4, 5
 - e. Venous drainage mainly to axillary vein but some to internal mammary and intercostal veins
2. Lymphatics:
 - a. 97% drainage to axilla
 - b. 3% drainage to internal mammary nodes
 - c. Level I: nodes lateral to lateral border of pectoralis minor
 - d. Level II: nodes lying beneath pectoralis minor
 - e. Level III: nodes medial to medial border of pectoralis minor and extending to apex of the axilla
3. Nerve supply:
 - a. Cervical plexus: sensory branches of C3, 4 from supraclavicular nerve
 - b. Lateral branches of intercostal nerves:
 - i. Provide sensation to lateral side of breast
 - ii. Lateral 4th provides major sensory innervation to nipple (T4 dermatome)
 - c. Medial branches of intercostal nerves 2-7 provide sensation to medial breast

B. Breast Reconstruction:

1. Breast cancer now affects one in eight women over the course of their lifetime and is the leading cause of cancer related death in women.
2. The breast is a symbol and attribute of femininity

3. All patients that have undergone or will undergo mastectomy are entitled to breast reconstructive surgery covered by insurance (Women's Health Act, 1998)
 4. Surgeons need to understand individual needs with regard to acceptable results and range of preferences:
 - a. No reconstruction: women may choose to simply wear a prosthetic.
 - b. Reconstruction of breast mound to attain close to natural breast shape, feel, contour
 - c. Breast mound reconstruction may or may not be followed with nipple/areolar reconstruction depending on patient goals.
 - i. Post-mastectomy defects are usually complicated by complete loss of the nipple/ areolar complex and loss of skin.
 - ii. Previous irradiation may cause difficulties with wound healing, skin contraction, capsular contracture, fat necrosis, and discoloration.
 - iii. If desired, following unilateral breast reconstruction, the opposite breast can be contoured, using mastopexy, reduction or augmentation mammoplasty for improved symmetry. Women's Health Act of 1998 provides assurance that contralateral matching (symmetry) procedures are to be covered by insurance.
- C. Mastectomy options
1. Partial / lumpectomy: removal of the affected portion of the breast only. Often requires post-op radiation.
 2. Subcutaneous mastectomy: removal of all breast tissue with preservation of all skin, including nipple/ areolar complex. There may be a slightly increased risk of breast cancer / recurrence in the future. Care must be taken to select and counsel patients appropriately.
 3. Skin-sparing mastectomy: simple mastectomy with preservation of all skin except the nipple areolar complex and a 1-2cm margin around the biopsy site
 4. Simple (total) mastectomy: removal of all breast tissue, including nipple areola complex
 5. Modified radical mastectomy: removal of all breast tissue, nipple-areola complex, pectoralis fascia, as well as Level I and II lymph nodes
 6. Halsted radical mastectomy: removal of all breast tissue, nipple/ areolar complex, pectoralis major and minor muscles, muscular fascia, Level I, II, and III lymph nodes (this procedure does not improve disease control compared to modified radical mastectomy and is largely of historical interest now)
- D. Techniques of breast reconstruction:
1. Implant Based / Prosthetic:
 - a. Can be single stage (straight to implant) reconstruction or gradual tissue expansion with the use of sub-pectorally placed expanders, with eventual breast implant insertion once adequate skin expansion has occurred.
 - b. May utilize acellular dermal matrix for partial coverage of device.
 - c. Breast implants may be saline or silicone (silicone implants have long been approved by the FDA for use in patients following mastectomy and can offer a more natural feel).
 2. Autogenous:
 - a. Pedicled flaps:

- i. Latissimus dorsi myocutaneous flaps used widely (can be combined with breast implant, which is usually required for adequate volume)
 - ii. Pedicled TRAM flap using superior epigastric vessels for blood supply (rectus abdominus muscle is used as a "carrier" for the blood vessel)
- b. Free flaps:
 - i. Technically more demanding, requiring microvascular techniques
 - ii. Recipient vessels tend to be internal mammary vessels (or their breast perforators) or less commonly, the thoracodorsal vessels.
 - iii. Lower risk of partial flap loss and fat necrosis, but potential total flap loss
3. Types Free of flaps:
- a. TRAM (Transverse Rectus Abdominis Myocutaneous) flap
 - b. Muscle sparing TRAM flap
 - c. DIEP (Deep Inferior Epigastric Perforator) flap
 - d. SIEA (Superficial Inferior Epigastric Artery) flap
 - e. The first 3 flaps use the deep inferior epigastric vessels for blood supply, whereas the SIEA uses the superficial inferior epigastric vessels
 - f. SIEA has to be of adequate caliber (artery with a palpable pulse, vein >1mm) to be used for anastomosis (only 10% of women will have an adequate SIEA)
 - g. TRAM and the muscle-sparing TRAM flaps take some element of muscle tissue as well as the fat and skin as a "carrier" for the deep inferior epigastric vessels (technically easier)
 - h. DIEP and SIEA flaps are technically harder to do as they do not take any muscle from the abdominal wall and require dissection of the blood vessels away from the "carrier" rectus abdominis muscle (advantage of less abdominal wall donor site complications)
 - i. Clinical relevance of not taking any muscle is still under debate, but may be advantageous for women who are athletic
 - j. Gluteal artery perforator flap (GAP) is another option, but is generally reserved for patients without sufficient abdominal wall tissue or patients that have previously undergone abdominal wall surgery (e.g. abdominoplasty)
 - k. Transverse upper gracilis flap (TUG) is again another secondary option but has a high donor site morbidity
 - l. Turbocharging:
 - i. Vascular augmentation using the vascular sources within the flap territory
 - ii. Example: performing a DIEP flap to the recipient internal mammary vessels then anastomosing an additional vessel from this system
 - m. Supercharging:
 - i. Vascular augmentation using a distant source of vessels such as axillary or thoracodorsal vessels
 - ii. Example: performing a pedicled TRAM flap, then augmenting the flow by anastomosing the deep inferior epigastric vessels to the thoracodorsal vessels
- E. Nipple areolar complex reconstruction
1. Nipple sharing (graft from the contralateral nipple) if available
 2. Local skin flaps +/- use of cartilage or acellular dermal matrix graft
 3. Intra-dermal color tattoo to match opposite nipple
 4. In-situ or remote-donor skin graft may also be used for areola

F. Breast Reduction

1. Indications:
 - a. Physical:
 - i. Neck, back, shoulder pain
 - ii. Shoulder grooving, bra straps cutting into shoulders
 - iii. Infection and maceration within inframammary fold (intertrigo)
 - iv. Neurological sequelae
 - b. Psychological:
 - i. Embarrassment
 - ii. Self-consciousness
 - iii. Loss of sexual appeal and femininity
2. Techniques:
 - a. Traditional: Wise pattern (inferior or central pedicle)
 - i. Advantage: predictable outcome
 - ii. Disadvantages: long scar length, "bottoming out" of breast, loss of superior pole
 - b. Vertical reduction pattern (superior or medial pedicle)
 - i. Advantage: attractive long term breast shape
 - ii. Disadvantages: steep learning curve, unattractive postoperative appearance
 - c. Large reductions may require nipple/areolar complex free grafting if pedicle is too long for blood supply
 - d. Liposuction can assist with "touch up"
3. Outcomes:
 - a. Excellent long term satisfaction
 - b. Lactation is possible if underlying glands are preserved
 - c. Nerve supply of nipple usually preserved, but outcomes can be variable
 - d. Occult breast cancer detected in 0.4% of specimens

II. CHEST WALL RECONSTRUCTION

- A. Goals of reconstruction:
 1. Rigid airtight cavity
 2. Protection of the thoracic and abdominal contents
 3. Optimization of respiration
 4. Obliteration of dead space for intrathoracic defects
 5. Stable soft tissue coverage
 6. Aesthetic reconstruction (whenever possible)
- B. Soft tissue chest wall defects:
 1. VAC therapy can be utilized
 2. Regional muscle flaps most frequently used:
 - a. Pectoralis major
 - b. Latissimus dorsi
 - c. Serratus anterior
 - d. Rectus abdominis
 3. Microvascular free flaps (when regional flaps have failed or are unavailable):
 - a. Contralateral latissimus dorsi

- b. Antero-lateral thigh (ALT)
 - c. Tensor Fascia Lata
 - d. Multiple recipient vessels are available for microvascular anastomosis (e.g., thoracodorsal system, transverse cervical, thyroacromial trunk)
- C. Skeletal chest wall defects:
1. Indications / Need for reconstruction (to avoid flail chest)
 - a. En bloc resection resulting in a defect larger than 5 cm or four or more ribs
 - b. Anterior and posterior defects are typically better tolerated than lateral defects
 - c. In patients with prior radiation, even larger defects may be tolerated owing to fibrosis
 - d. Small defects of skeletal chest wall are most often functionally insignificant
 2. Autogenous
 - a. Rib grafts, free or vascularized
 - b. Fascia
 - c. Pedicled or free flaps (especially those containing fascia like the ALT)
 3. Alloplastic
 - d. Mesh - several synthetics available and most commonly used is a polypropylene knitted mesh (Prolene / Marlex). Others options: PTFE, polyglactin, polyster
 - e. Bioprosthetic mesh: Human acellular dermal matrices (Alloderm, Allomax...) and xenograft (Strattice...)
 - f. Larger reconstruction may also incorporate methyl-methacrylate to enhance chest wall stabilization
 - g. Frequently, vascularized soft tissue (as described above) is needed to cover these forms of skeletal reconstruction
- D. Sternal wound infection and dehiscence:
1. Mediastinitis and sternal wound dehiscence are devastating and life threatening complications of median sternotomy incision
 2. Occurs in 0.25-5% of cases
 3. Sternal dehiscence involves separation of the bony sternum and often infection of the deep soft tissues, referred to as mediastinitis, as well as osteomyelitis.
 4. Mortality rates in initial studies near 50% (significantly improved with better ICU and surgical care)
 5. Treatment options:
 - a. Early debridement/ wound excision
 - b. VAC therapy
 - c. Infection control with directed antimicrobial therapy based on blood and tissue culture
 - d. Development of granulation tissue
 - e. Further debridement if necessary
 - f. Rigid sternal plate fixation (provides improved chest and respiratory function as well as cosmetic appearance)
 - g. Primary rigid sternal plate fixation (in lieu of circlage wires) has been shown to decrease complications
 - h. Primary wound closure +/- myocutaneous, muscle, or omentum flaps (usually pectoralis major but others have been described: rectus abdominis, latissimus dorsi and omentum)

- E. Congenital chest wall defects:
1. Pectus excavatum (sunken chest) and pectus carinatum (pigeon chest)
 - a. Pectus excavatum 10 times more common than pectus carinatum
 - b. Indications for treatment:
 - i. Aesthetic
 - ii. Relief of cardio respiratory dysfunction in severe cases
 - iii. Costal cartilage disorganized growth
 - c. Pectus excavatum treatment:
 - i. Nuss procedure:
 - a) Curved, custom-shaped, stainless steel rod is guided through the rib cage and beneath the sternum
 - b) Rod then rotated, turning the curved portion against the chest wall, pushing the ribs and sternum out
 - d. Pectus carinatum treatment:
 - i. Multiple osteotomies of sternum and affected ribs
 2. Poland's Syndrome:
 - a. Etiology: subclavian artery supply disruption sequence
 - b. Features:
 - i. Absence of sternal head of pectoralis major
 - ii. Hypoplasia of breast or nipple
 - iii. Deficiency of subcutaneous fat and axillary hair
 - iv. Bony abnormalities of anterior chest wall
 - v. Syndactyly or hypoplasia of ipsilateral extremity
 - vi. Shortening of forearm
 - c. Treatment:
 - i. Can place tissue expander in adolescent female and expand as contralateral breast develops and replace with a permanent implant when the patient reaches breast maturity.
 - ii. May also await full breast development
 - iii. Breast reconstruction (flaps, implants)
 - iv. Can use innervated ipsilateral latissimus to recreate anterior axillary fold

III. ABDOMINAL WALL RECONSTRUCTION

- A. Clinical problems that require abdominal wall reconstruction:
 1. Tumor resection
 2. Infection (necrotizing fasciitis)
 3. Trauma
 4. Recurrent ventral wall hernias
 5. Congenital abdominal wall defects (gastroschisis, omphalocele)
- B. Principles for abdominal wall reconstruction:
 1. To protect and cover the intra-abdominal viscera
 2. To repair and prevent herniation with strong fascial support
 3. To achieve acceptable surface contour
- C. Algorithm for abdominal wall reconstruction:
 1. Primary closure (avoid tension)
 2. Mesh (10% hernia recurrence, 7% infection)

3. Allografts / human acellular dermal matrices (ie Alloderm, Allomax)
4. Autogenous skin grafts (over viscera with or without mesh and omentum)
5. Methods of reconstruction relying on local tissues (not applicable in patients who have had multiple previous procedures):
 - a. Components separation release
 - i. Relaxing incisions can be made unilaterally or bilaterally in the external oblique fascia, just lateral to rectus muscle
 - ii. Enables medial transposition of rectus muscle sheath
 - iii. Advancement attainable: 10cm in epigastrium, 20cm at umbilicus and 6cm in suprapubic region
 - b. Tissue expansion
- D. Pedicled muscle and myocutaneous flaps (when synthetic mesh and fascial separation are contraindicated)
 1. Antero-lateral thigh (ALT)
 2. Tensor fascia lata
 3. Gracilis
 4. Rectus femoris
 5. Propeller flaps (flaps pedicled on a particular perforator)
- E. Free flaps
- F. Split thickness skin and/or synthetic mesh directly over bowel (in emergency situations; will often require further reconstructive surgery)
- G. VAC use can be integrated into the treatment of patients with compromised wound healing
 1. Cases of enteric fistula formation have been associated with the VAC; paradoxically, however, VAC has also been used successfully for the management of fistulae

IV. PRESSURE ULCERS

- A. Unrelieved pressure can lead to tissue ischemia in deep tissue layers near bony prominences leading to tissue necrosis
- B. Can develop within 2 hours of unrelieved pressure
- C. Decubitus was term to describe lying position, however, any area that has sustained pressure can develop into an ulcer, including the sitting position
- D. Term "pressure ulcer" is now preferred over "decubitus ulcer"
- E. Pressure sores often have "iceberg phenomenon"
 1. Since skin can withstand ischemia much better than fat or muscle, a small skin wound on surface can reflect a large amount of deeper tissue necrosis underneath.
- F. Common areas include:
 1. Occipital region
 2. Spine
 3. Sacrum
 4. Coccyx
 5. Ischial tuberosity
 6. Greater trochanter
 7. Heel
 8. Malleoli
- G. Other factors contributing to pressure sore formation:

1. Altered sensory perception
 2. Incontinence
 3. Exposure to moisture
 4. Altered activity and mobility
 5. Friction and shear forces (damage to superficial layers can allow bacteria to colonize and result in deeper ulceration)
 6. Muscle contractures
 7. Cognitive impairment
 8. Immunocompromise
 9. Prolonged ventilator dependence
- H. Staging system:
1. Stage I: Erythema of the skin (may be overlooked in dark-skinned patients)
 2. Stage II: Skin ulceration and necrosis into subcutaneous tissue
 3. Stage III: Grade II plus muscle necrosis
 4. Stage IV: Grade III plus exposed bone/joint involvement
- I. Incidence:
1. Bed-bound hospital patients: 10-15%
 2. ICU patients: 33%
 3. Hip fracture patients: up to 66%
- J. Non-surgical treatment:
1. Prevention is the best treatment
 - a. Keep skin clean and dry
 - b. Appropriate nursing care, including turning the patient every 2 hours (avoid dragging/shearing skin of the patient while repositioning)
 - c. Optimizing nutrition
 - d. Relieving pressure using air mattresses, cushions, heel protectors
 - e. Air fluidized beds (Clinitron®) gold standard for ulcer prevention
 2. Systemic infection/sepsis unlikely with pressure ulcer (unless immunocompromised): look for other source, e.g., urinary tract infection or respiratory tract when patients with pressure ulcers present with fevers
 3. If localized infection is present (look for signs of local cellulitis) topical antimicrobial agents (Silvadene, Sulfamylon) can be used
 4. Bone biopsy best method to assess osteomyelitis vs. osteitis
 5. Can direct antibiotic therapy to treat osteomyelitis, but virtually impossible to eradicate infection
 6. MRI may be helpful as imaging study, while bone scans are often nonspecific due to presence of periostitis associated with open wounds
 7. Long term antibiotics are not indicated
 8. Ulcer closure may be accelerated using topical protein growth factors
 9. Stage III patients require sharp debridement, highly absorptive dressings (alginates, hydrocolloid beads, foams, hydrogels)
 10. VAC therapy may be beneficial to assist closure
- K. Surgical treatment:
1. Due to high recurrence rates, surgery tends to be reserved for patients with reversible pathologies
 2. Patient motivation is an important determinant of recurrence risk in the alert patient

3. Excisional debridement of ulcer and bursa and any heterotopic calcification
4. Partial or complete osteotomy to reduce bony prominence – may lead to new pressure ulcers elsewhere (be careful when off-loading)
5. Closure of the wound with healthy, durable tissue that can provide adequate padding over the bony prominence (myocutaneous vs. fasciocutaneous flap)
6. Aftercare including appropriate surfaces and wound management are paramount
7. Lifestyle and activity modification often required in order to reduce recurrence risk

V. EXTERNAL GENITALIA

- A. Congenital defects:
1. Male child with congenital genital defect should not be circumcised to preserve tissue that may be needed for surgery
 2. Hypospadias
 - a. Urethral opening develops abnormally, usually on the underside of the penis
 - b. Occurs in 1/350 male births
 - c. Can be associated with undescended testicles
 - d. Operation around 1 year of age (stimulation with testosterone may increase penile size and aid in wound healing)
 - e. Distal cases can be repaired using local tissue flaps or urethral advancement
 - f. Proximal cases can be repaired using graft urethroplasty or vascularized prepuce flap urethroplasty
 3. Epispadias and exstrophy of the bladder
 - a. Failure or blockage of normal development of the dorsal surface of the penis, abdomen, and anterior bladder wall
 - b. 1/30,000 births, three times more common in males
 - c. Epispadias treated similarly to hypospadias, with local tissue flaps
 - d. Bladder exstrophy requires staged, functional reconstruction
 - i. Neonatal period: bladder is closed
 - ii. 1-2 years: epispadia repair
 - iii. 3-4 years: bladder neck reconstruction
 4. Ambiguous genitalia
 - a. Evaluation and management requires a team approach and great sensitivity towards the family
 - b. Caused by adrenal hyperplasia, maternal drug ingestion, hermaphroditism
 - c. Karyotype should be obtained immediately
 - d. Pelvic ultrasound can be performed to assess Müllerian anatomy
 - e. Gender assignment needs to take multiple biopsychosocial factors into account
 5. Vaginal agenesis
 - a. 1 in 5000 female births
 - b. Absence of proximal portion of vagina in an otherwise phenotypically, chromosomally, and hormonally intact female
 - c. Often undiagnosed until amenorrhea noted
 - d. Reconstruction in puberty by progressive dilation, grafts, or flaps
- B. Trauma:
1. Penile and scrotal skin loss injuries

- a. Can bury shaft of penis temporarily then use full thickness or split thickness skin graft
- b. Scrotum can have split thickness skin grafted
- 2. Penetrating injuries to penis
 - a. Require immediate operative repair
- 3. Penis amputation
 - a. Reattachment is feasible with cold ischemia time of up to 24 hours
 - b. Debride wound and opposing surfaces thoroughly
 - c. Microsurgical approach is preferable
 - i. Urethra re-approximated with Foley as indwelling stent and suprapubic catheter for bladder drainage
 - ii. Dorsal arteries, veins, nerves reconnected
 - iii. Corpora reattached
- 4. Testicle amputation
 - a. microsurgical replantation
 - b. future prosthetic replacement
- C. Phallic reconstruction
 - 1. Subtotal penile loss: release penile suspensory ligament, recess scrotum and suprapubic skin, apply skin graft to remaining stump
 - 2. Total penile loss:
 - a. Pedicled flaps – ALT, tubed abdominal flap, gracilis myocutaneous flap, groin flap
 - b. Free flap – radial forearm, ulnar forearm, ALT, osteocutaneous fibula
 - c. Can be done in one-stage procedure, sensation may be restored, better appearance, competent urethra, may have adequate rigidity (fibula)
 - d. May place inflatable / malleable prosthesis in secondary surgery
- D. Vaginal reconstruction
 - 1. Lining
 - a. Full-thickness skin grafts
 - b. Skin flaps
 - c. Intestinal segments
 - 2. Pedicled VRAM (vertical rectus abdominus myocutaneous) flap
 - 3. Pudendal thigh flap
 - 4. Rectosigmoid vaginoplasty
- E. Infectious:
 - 1. Fournier's gangrene and other necrotizing infections
 - a. Multiple organs commonly cultured
 - b. Infection begins at skin, urinary tract, rectum and spreads to penis, scrotum, perineum, abdomen, thighs, and flanks in the Dartos, Scarpa's, and Colles fascia
 - c. Corpora bodies, glans, urethra, and testes not usually involved
 - d. Treatment primarily extensive surgical debridement of involved tissue
 - e. Drains placed as deemed necessary
 - f. High dose, broad-spectrum antibiotics
 - g. Urinary diversion
 - h. Colostomy if cause from rectal/ perirectal area
 - 2. Hidradenitis suppurativa

- a. Chronic condition
- b. Multiple painful, swollen lesions in the axilla, groin, and other parts of the body that contain apocrine glands
- c. Can involve adjacent subcutaneous tissue and fascia
- d. Sinus tracts form (which can become draining fistulas) in the apocrine gland body areas
- e. Treatment of infected lesions is incision and drainage
- f. Cure may require massive surgical excision to eliminate all apocrine glandular tissue with healing by secondary intention
- g. Antibiotics: Tetracycline and erythromycin may be helpful long-term

CHAPTER 5 – BIBLIOGRAPHY

BREAST, TRUNK AND EXTERNAL GENITALIA

1. Greer SE, Benhaim P, Lorenz HP, Chang J, Hedrick MH. Handbook of Plastic Surgery. Marcel Dekker New York 2004.
2. Thorne CH, Bartlett SP, Bealsey RW, Aston SJ. Grabb and Smith's Plastic Surgery 6th Edition. Lippincott Williams and Wilkins, Philadelphia 2006.
3. Mathes S and Nahai F. **Reconstructive Surgery: Principles, anatomy and technique.** New York, Churchill Livingstone, 1997.
4. Serletti JM, Fosnot J, Nelson JA, Disa JJ, Bucky LP. Breast reconstruction after breast cancer. *Plast reconstr Surg* 127(6):124e-135e.
5. Hammond DC, Loffredo M. Breast reduction. *Plast Reconstr Surg* 129(5):829e-839e.
6. Netscher DT, Baumholtz MA. Chest reconstruction: Anterior and anterolateral chest wall and wounds affecting respiratory function. *Plast Reconstr Surg* 124(5):240e-52e.
7. Netscher DT, Baumholtz MA, Bullocks J. Chest reconstruction: Regional reconstruction of chest wall wounds that do not affect respiratory function (axilla, posterolateral chest, and posterior trunk). *Plast Reconstr Surg* 124(6):427e-35e.
8. Rubayi S, Chandrasekhar BS. Trunk, abdomen and pressure sore reconstruction. *Plast Reconstr Surg* 128(3):201e-215e.
9. Walsh PC, Retik AB, Vaughan ED, Wein AJ. Campbell's Urology 8th Edition. Saunders Philadelphia 2002.

CHAPTER 6

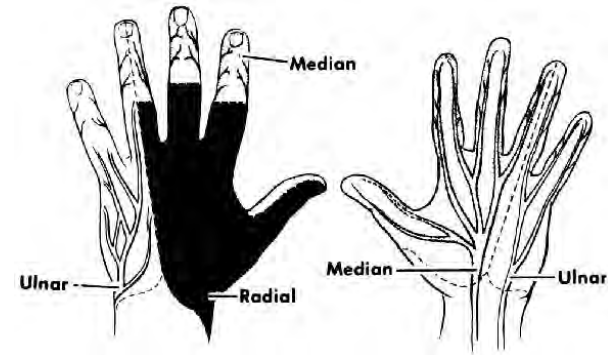
UPPER EXTREMITY

The surgical treatment of hand problems is a specialized area of interest in plastic surgery. The hand is a unique organ which transmits sensations from the external environment to us as well as allowing us to modify and interact with the external environment. The hand is made up of many finely balanced structures. It must function with precision, as in writing, as well as with strength, as in hammering.

I. HAND ANATOMY

A. Nerves

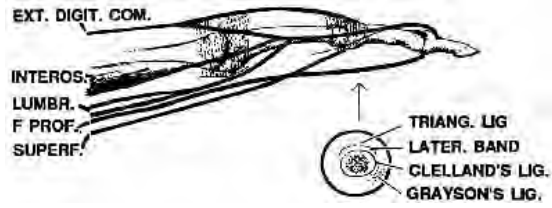
1. Sensory - median, ulnar, radial (Fig. 6-1)
2. Motor - intrinsic muscles of hand
 - a. Median nerve - thenar muscles, radial lumbricals
 - b. Ulnar nerve - interossei, ulnar lumbricals, hypothenar muscles



(FIGURE 6-1)


B. Muscles and tendons

1. Flexor system (Fig. 6-2)
 - a. Extrinsic flexors - Flexor digitorum profundus attaches to distal phalanx and bends the DIP (distal interphalangeal) and PIP (proximal interphalangeal) joints. Flexor digitorum superficialis attaches to middle phalanx and bends PIP (proximal interphalangeal) joint.
 - b. Intrinsic flexors - Lumbricals bend the MCP (metacarpal-phalangeal) joints



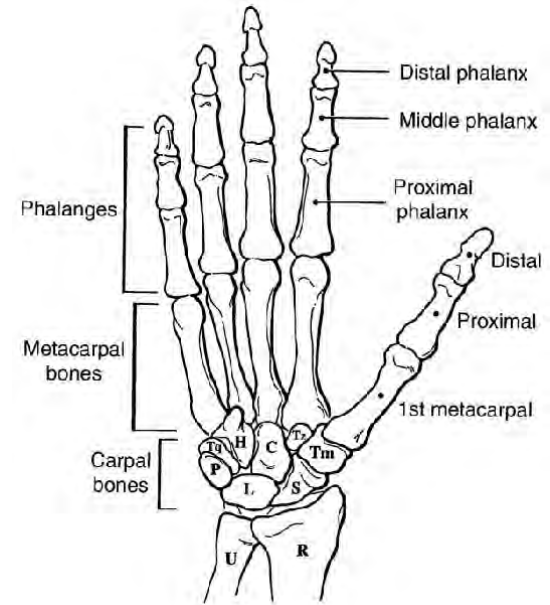
(FIGURE 6-2)

2. Extensor system (Fig. 6-3)
 - a. Extrinsic extensors join the extensor hood at the proximal phalanx, and extend the proximal phalanx at the MCP joint.
 - b. Intrinsic (interossei and lumbricals) pass volar to the axis of the MCP joint (where they act as flexors) and move dorsal to the axis of the PIP joint to insert on the dorsal distal phalanx. They act as extensors to the PIP and DIP joints



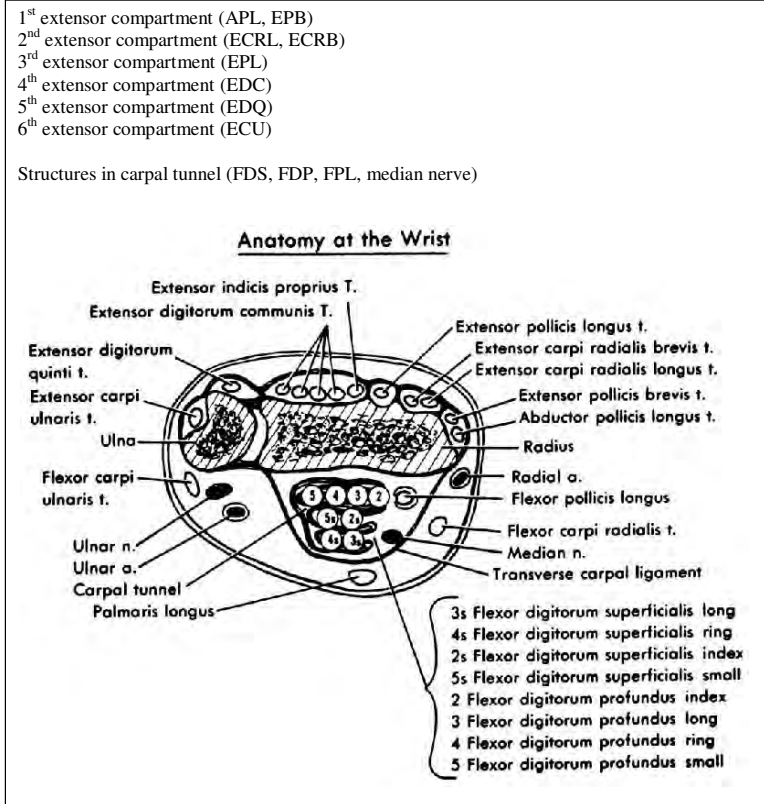
(FIGURE 6-3)

C. Skeleton (Fig. 6-4)



(FIGURE 6-4)*

D. Wrist – a large number of tendons, nerves and vessels pass through a very small space, and are vulnerable to injury (Fig. 6-5)



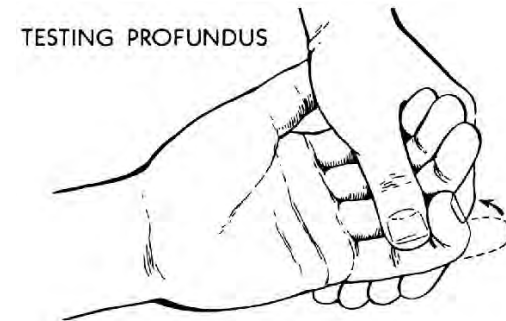(FIGURE 6-5)

II. INITIAL EVALUATION OF THE INJURED HAND

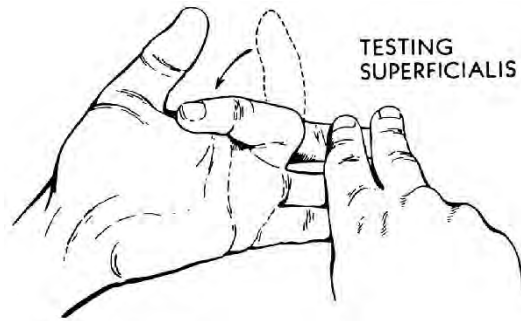
A. History

1. Time and place of accident
2. Agent and mechanism of injury

3. First aid given
 4. Right or left hand dominance
 5. Occupation
 6. Age
- B. Examination
1. Observation
 - a. Position of fingers - normally slightly flexed. An abnormally straight finger might indicate a flexor tendon injury (the unopposed extensors hold the finger straight)
 - b. Sweating patterns (lack of perspiration indicates denervation)
 - c. Anatomic structures beneath the injury
 2. Sensory - must test prior to administering anesthesia
 - a. Pin to measure sharp/dull sensitivity, paper clip
 - b. Test all sensory territories (median, ulnar, radial)
 - c. Test both sides of each finger
 3. Motor
 - a. Profundus - stabilize PIP joint in extension, ask patient to flex fingertip (Fig. 6-6)
 - b. Superficialis - stabilize other DIP joints in extension. This neutralizes profundus action.
 - i. Ask patient to flex unstabilized finger (Fig. 6-7)
 - c. Motor branch of median nerve; test palmar abduction of thumb against resistance
 - d. Motor branch of ulnar nerve; ask patient to fully extend fingers, then spread fingers or cross fingers
 - e. Extensor tendons
 - i. Ask patient to extend fingers at MCP joints (tests long extensors)
 - ii. Ask patient to extend PIP, DIP joints with MPs flexed (tests intrinsic extensors)

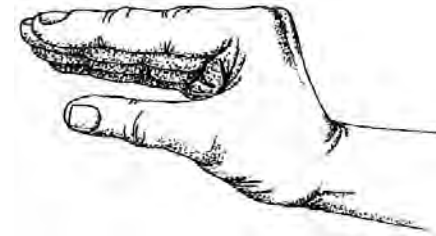


(FIGURE 6-6)



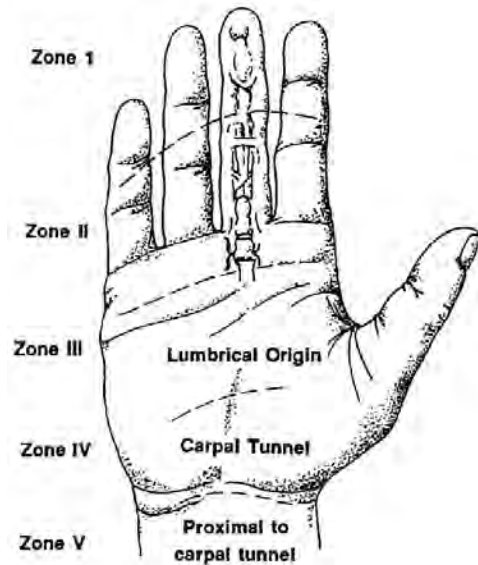
(FIGURE 6-7)

4. Vascular
 - a. Color – nailbed should be pink, blanch with pressure, and show capillary refill within two seconds
 - b. Temperature – finger or hand should be similar in temperature to uninjured parts
 - c. Turgor – pulp space should be full without wrinkles
- C. Early care
 1. Use pneumatic tourniquet or BP cuff inflated to 250mmHg to control bleeding for examination and treatment. An awake patient will tolerate a tourniquet for 15-30 min
 2. If bleeding is a problem, apply direct pressure and elevate until definitive care available
 - a. Do not clamp vessels
 - b. Tourniquet may be used as last resort, but must be released intermittently
 3. Splint in safe position if possible (Fig. 6-8)
 - a. Position where collateral ligaments are at maximum stretch, so motion can be regained with least effort Fig. 6-6
 - b. Positioning - wrist extended (30 degrees), MCP joints flexed (60-70 degrees), IP joints straight, thumb abducted and rotated in opposing position
 - c. Proper splinting prevents further injury, prevents vessel obstruction, prevents further tendon retraction
 4. All flexor tendon, nerve and vascular injuries, open fractures, and complex injuries are managed in the operating room
 5. Tetanus prophylaxis and antibiotic coverage as indicated



(FIGURE 6-8)

- D. Definitive treatment
 1. Thorough cleaning of entire hand and forearm, with wound protected
 2. Apply sterile drapes
 3. Inspect wound - use tourniquet or BP cuff for hemostasis
 4. Wound irrigation with normal saline
 5. May need to extend wound to inspect all vital structures
 6. Assure hemostasis with fine clamps and cautery
 7. Nerve injuries should be repaired with magnification
 8. Tendons are repaired primarily.
 - a. Flexor tendon injuries in Zone II, "no man's land" (Fig. 6-9) should be repaired by a trained hand surgeon
 - b. If a hand surgeon is not available, clean and suture the skin wound, splint the hand, and refer as soon as possible for delayed primary repair. Repair should be done within 10 days
 9. Reduce fractures and dislocations, apply internal or external fixation if needed
 10. Postoperative dressings
 - a. Splinting should be in safe position when possible, but alternative positioning may be required to protect tendon or nerve. Splint extensor tendon repairs in extension, and dorsal blocking splint for flexor tendon repairs
 - b. Dressings should not be tight



Flexor zones of hand.
(FIGURE 6-9)

III. SPECIAL INJURIES

- A. Fingertip - most common injury
 1. Tip amputations
 - a. Basic principles - maintain length, bulk and sensibility
 - b. Treatment options include secondary healing, skin graft, flap
 2. Nailbed injury
 - a. Nailbed should be repaired with fine chromic gut suture
 - b. Nail can be cleaned and replaced as a splint, or silastic sheet used as splint to prevent adhesion of the eponychial fold to the nailbed
- B. Amputation
 1. Indications for replantation - thumb, multiple fingers, and children. Single finger replantations often not indicated. Must discuss with replant team.
 2. Care of amputated part

- a. Remove gross contamination and irrigate with saline
- b. Wrap part in gauze moistened in saline, place in clean plastic bag or specimen cup, seal
- c. Lay container on ice, or float on ice cubes in water. Don't immerse part directly in ice water or pack directly in ice - it may freeze
3. Care of patient
 - a. Do not clamp vessels
 - b. Supportive care
 - c. X-ray stump and amputated part
- C. Burned hand
 1. Initial treatment
 - a. Cleanse wound, debride broken blisters
 - b. Evaluate blood supply - circumferential full thickness burns may require escharotomy
 - c. Apply occlusive dressings to reduce pain
 - d. Immobilize in safe position
 - e. Refer to plastic surgeon if burn is extensive or may require grafting
 2. Hand therapy may be needed to maintain motion

IV. INFECTIONS

- A. General principles
 1. Infection can be localized by finding:
 - a. The point of maximum tenderness
 - b. Signs of local heat
 - c. Overlying skin edema
 - d. Pain on movement
 2. A fever usually denotes lymphatic involvement
 3. Pressure from edema and pus in a closed space can produce necrosis of tendons, nerves, blood vessels, and joints in a few hours. Extreme cases can lead to amputation and even death.
- B. Treatment principles
 1. Surgical drainage, cultures
 2. Immobilization in safe position, elevation
 3. Antibiotics
- C. Special infections
 1. Paronychia - infection of the lateral nail fold Treatment: if early, elevation of skin over nail to drain. If late, with pus under nail, must remove portion of nail
 2. Felon
 - a. Pus in pulp space of fingertip - closed space without ability to expand - very painful
 - b. Pressure of abscess may impair blood supply
 - c. Treatment is drainage over point of maximal tenderness - lateral if possible
 3. Subcutaneous abscess - incise and drain with care not to injure digital nerve. Be alert to possibility of foreign body
 4. Tenosynovitis - infection of tendon sheath
 - a. Diagnostic signs (kanavel's signs)

- i. Fusiform swelling of finger
 - ii. Finger held in slight flexion
 - iii. Pain with passive extension
 - iv. Tenderness over flexor tendon sheath
 - b. Treatment is to open and irrigate tendon sheath. Untreated infection can destroy the tendon within hours
- 5. Human bite
 - a. Have high index of suspicion – patients are often unwilling to admit being in a fight. Most common site over a knuckle
 - b. Debride, cleanse thoroughly, culture
 - c. Must rule out penetration of joint space – may need to explore in OR
 - d. Broad spectrum antibiotics – often I.V.
 - e. Do not suture wound

V. FRACTURES

- A. General principles
 - 1. Inspect, palpate, x-ray in multiple planes – AP, true lateral, oblique
 - 2. Reduce accurately
 - 3. Immobilize for healing
 - 4. Hand therapy to maintain motion
- B. Specific fractures
 - 1. Metacarpal fractures
 - a. Boxer's fractures – fracture of 4th or 5th metacarpal neck. Can accept up to 30 degrees of angulation, if no malrotation present. Treatment can range from gentle protective motion if Minimally displaced to closed reduction and cast to open reduction and internal fixation
 - b. Metacarpal shaft fractures – must check for rotatory deformity. Flex all fingers. If involved finger overlaps another, there is rotation at the fracture site which must be reduced. Unstable fractures must be fixed with pins or plates and screws
 - 2. Phalangeal fractures
 - a. Unstable fractures require internal or percutaneous fixation
 - b. Joint surfaces should be anatomically reduced
 - 3. Tuft fractures (distal phalanx)
 - a. If crushed, mold to shape
 - b. Repair associated nailbed injury if needed
 - c. Splint for comfort (DIP only) for 1-2 wks

VI. JOINT INJURIES

- A. Dislocation
 - 1. If already reduced, test for stability through arc of motion. Test collateral ligament stability with radial and ulnar stressing at affected joint. Test MPJ in flexion and IP joints in extension.
 - 2. Most can be treated with closed reduction; open reduction can be necessary if supporting structures prevent the reduction (e.g. metacarpal head through extensor mechanism)
- B. Ligamentous injury - usually lateral force

- 1. Gameskeeper's thumb - rupture of ulnar collateral ligament of MP joint
 - 2. Wrist injury - multiple ligaments can be involved. Diagnosis may require MRI arthrogram or arthroscopy. Clinical diagnosis by pattern of pain, x-rays, palpation for abnormal movement.
 - C. Treatment
 - 1. Immobilize 2-3 weeks for digital joint injury (MP or IP dislocation), then protected motion
 - 2. Thumb MPJ and wrist sprains require 6 weeks immobilization. (some, e.g. thumb ulnar collateral ligament, might need operative repair)

VII. CONGENITAL DEFECTS

- A. Classification system (Table 6-1)

I.	Failure of formation of parts
A.	Transverse
B.	Longitudinal
II.	Failure of separation of parts
III.	Duplication of parts
IV.	Overgrowth of parts
V.	Undergrowth of parts
VI.	Congenital constriction bands
VII.	Generalized skeletal abnormalities
Adapted from Swanson, A.B.: <i>J Hand Surg</i> 1:8, 1976.	

Table 6-1

- B. Common defects
 - 1. Polydactyly - most common. Duplication of fingers, usually border digits. Duplication of 5th finger is common autosomal dominant trait in African-Americans. Thumb duplication often requires reconstructive surgery
 - 2. Syndactyly - 2nd most common - May be simple, involving skin only, or complex, involving bone
- C. Treatment - goal to decrease deformity and improve function
 - 1. Some problems are treated in infancy – e.g. splinting for club hand, thumb reconstruction
 - 2. Some treated by 12 months, before handedness develops – e.g. separation of syndactyly
 - 3. Some require multi-stage procedures – e.g. club hand

VIII. HAND TUMORS**A. Benign**

1. Ganglion cysts – most common
 - a. Synovial cyst of joint or tendon sheath
 - b. Treatment is observation or excision
2. Giant cell tumor
3. Glomus tumors – of thermoregulatory neuromyoarterial apparatus. Presents with pain and temperature sensitivity at base of nail. Located in nail matrix.
4. Bone tumors – enchondroma, Osteoid osteoma

B. Malignant

1. Skin cancers (e.g. basal cell, squamous cell, melanoma)
2. Malignant bone tumors are uncommon in hand

IX. MISCELLANEOUS

- A. Rheumatoid arthritis – synovial hypertrophy can lead to nerve compressions (carpal tunnel syndrome), joint destruction. Hand surgeons can perform synovectomy, joint replacement, carpal tunnel release
- B. Dupuytren's contracture
 1. Fibrous contraction of palmar fascia causes flexion contractures of fingers
 2. Treatment is surgical excision or Xiaflex (collagenase) for MPJ contractures
- C. Nerve compressions – compression of nerve by overlying muscle, ligament or fascia
 1. Example: carpal tunnel – compression by transverse carpal ligament
 2. Diagnosis by symptoms, exam, and EMG
 3. Treatment options include splinting, steroid injections, surgery

CHAPTER 6 - BIBLIOGRAPHY**UPPER EXTREMITY**

1. Achauer, B.H. Plastic Surgery: Indications, Operations, Outcomes. St. Louis: Mosby, 2000.
2. Aston, S.J. et al. (eds.) Grabb and Smith's Plastic Surgery. 5th Ed. Baltimore Lippincott, Williams and Wilkins, 1997.
3. Green, D.P. Operative Hand Surgery. New York: Churchill Livingstone, 1996.
4. McCarthy, J. Plastic Surgery. (8 vols). St. Louis: Mosby, 1990.

*Fig. 6-4 reprinted with permission from Marks, M.W., Marks, C. Fundamentals of Plastic Surgery. Philadelphia: W.B. Saunders Co., 1997.

CHAPTER 7

LOWER EXTREMITY

The plastic and reconstructive surgeon is often called upon to treat many wound problems of the lower extremity. These include leg ulcers of various etiologies, trauma with extensive soft tissue loss or exposed bone, vascular or neural structures, and lymphedema.

I. ULCERATIONS

An ulcer is an erosion in an epithelial surface. It is usually due to an underlying pathophysiological process. The proper treatment depends upon the etiology

A. Etiology

1. Venous Stasis Ulcer
 - a. Due to venous hypertension; related to venous valvular incompetence - usually found over the medial malleolus
 - b. Increased edema
 - c. Increased hemosiderin deposition (dark discoloration)
 - d. Not painful
2. Ischemic Ulcer
 - a. Due to proximal arterial occlusion
 - b. Usually more distal on the foot than venous stasis ulcers
 - c. Most often found on the lateral aspects of the great and fifth toes, and the dorsum of the foot
 - d. No edema
 - e. No change in surrounding pigmentation
 - f. Painful
 - g. Doppler ankle/brachial indices 0.1-0.3
 - h. Indicates advanced atherosclerotic disease
 - i. Dirty, shaggy appearance
3. Diabetic Ulcer
 - a. Due to decreased sensation (neurotrophic) or occasionally decreased blood flow
 - b. Usually located on plantar surface of foot over metatarsal heads or heel
 - c. Edema ±
 - d. No change in surrounding pigmentation
4. Traumatic Ulcer
 - a. Failure to heal is usually due to compromised area of the ulcer, scar tissue, and surrounding blood supply and an unstable scar
 - b. Usually occurs over bony prominence
 - c. Edema ±
 - d. Pigmentation change ±
 - e. Pain ±
5. Pyoderma Gangrenosum
 - a. Frequently associated with arthritis and/or inflammatory bowel disease or an underlying carcinoma
 - b. Clinical diagnosis - microscopic appearance non-specific

- c. Zone of erythema at advancing border of the lesion
- B. Treatment

Each ulcer type requires accurate diagnosis, specific treatment of the underlying etiology, and care of the wound. Not all ulcers of the lower extremity will require surgical intervention when appropriate management is pursued. The key to healing these ulcers is wound hygiene, correction of the underlying problem, and specific surgical intervention when appropriate. The plastic surgeon is an integral member of the treatment team from the onset of the problem. Remember that two different predisposing conditions may occur in the same patient. If so, the treatment must address both conditions.

1. Venous Stasis Ulcers

- a. Most will heal if venous hypertension is controlled
- b. Decrease edema with constant bed rest with foot elevation
- c. Clean wound 2-3 times a day with soap and water
- d. Topical antimicrobials may be required
- e. Systemic antibiotics are required if cellulitis is present or bacteremia occurs
- f. "Unna boots" may heal ulcers in patients who are noncompliant with bed rest or must continue to work. These are changed on a weekly or bi-weekly basis
- g. Pentoxifylline therapy in combination or as substitute for compression therapy if compression is not tolerated.
- h. Surgical treatment requires excision of the entire area of the ulcer, scar tissue, and surrounding area of increased pigmentation (hemosiderin deposition). Subfascial ligation of venous perforators is also performed
 - i. Skin grafting of large areas is usually not a problem. Intact periosteum or paratenon will take a graft well
 - ii. Free flaps can be effective for recalcitrant ulcers
- i. Pressure gradient stocking (such as Jobst™ garments) and a commitment to avoiding standing for long periods of time are necessary for long term success

2. Ischemic Ulcers

- a. Most require revascularization based upon angiographic findings
- b. Control associated medical problems such as congestive heart failure, hypertension, diabetes, etc.
- c. Bed rest without elevation of the foot of the bed
- d. Topical and/or systemic antibiotics are usually required
- e. If possible, it is best to perform bypass surgery first, and then healing of the ulcer by any means will be easier
- f. Usually a skin graft will close the wound; flap closure may be required. A more proximal amputation may be required if revascularization is not possible

3. Diabetic Ulcer

- a. Debride necrotic tissue and use topical and systemic antibiotics to control the infection
- b. Be conservative in care; early amputation is detrimental since many patients will have life-threatening infections in the other leg within a few years
- c. After control of bacterial contamination, small ulcers may be excised and closed primarily; larger ulcers may require flap coverage

- d. Treatment should also include resection of underlying bony prominence
 - e. Rule out proximal arterial occlusion and improve arterial inflow when needed
 - f. Postoperative diabetic foot care at home is paramount to proper management. Patient education in caring for and examining their feet is extremely important
 - g. Hyperbaric oxygen and tissue cultured skin substitutes may be therapies which can assist in ulcer resolution.
4. Traumatic Ulcer
 - a. Nonhealing is usually secondary to local pathology
 - b. Resection of the ulcer, thin skin, and unstable scar is required
 - c. Reconstruction with a local or distant flap is required
 5. Pyoderma Gangrenosum
 - a. Very difficult
 - b. May include anti-inflammatory drugs or immunosuppressives, as well as local wound care agents
 - c. Success in treatment has been reported with hyperbaric oxygen in conjunction with local wound care

II. TRAUMA

Lower extremity trauma is frequently very complex, and often requires a team approach involving the orthopedic, vascular and plastic surgeons. Limb salvage with bipedal ambulation and normal weight bearing is the goal of all surgical intervention

A. Initial Management

1. All patients with lower extremity trauma should be evaluated for associated injuries, and treated according to ATLS criteria
2. All life threatening injuries (intracranial, intrathoracic, and intra-abdominal) should be addressed initially in the operating room
3. Surgical debridement of the wound in the operating room and irrigation with pulsatile jet lavage of a physiologic solution is the proper initial management. Specific management depends upon the level of injury, presence or absence of bony neurological injury
4. Limb threatening injuries of vascular interruption or open fracture are best assessed in the OR with radiologic backup
5. Fasciotomy is often required to maintain tissue perfusion in severe high energy or crush injuries
6. Intra-operative evaluation for viability utilizing visual and surgical techniques may be supplemented by intravenous fluorescein to assess the viability of degloved tissue

B. Level of Injury

1. Thigh

Usually managed with delayed primary closure or skin graft. An abundance of soft tissue in the thigh makes coverage of bone or vessels rarely a problem

- a. Open joint wounds are usually managed by the orthopedic service with profuse lavage and wound closure
- b. Extensive soft tissue loss will often require flap rotation – the tensor fascia lata, gracilis, rectus femoris, vastus lateralis, and biceps femoris are primarily utilized

- c. The medial and lateral heads of the gastrocnemius muscle are most often utilized to cover an open knee joint
2. Lower Leg
 - a. Paucity of tissue in the pre-tibial area results in many open fractures which cannot be closed primarily
 - b. General principles of wound closure and achieving bacterial balance prevail
 - c. Delayed primary closure, healing by secondary intention, or skin grafts are good alternatives in the management of wounds where bone or fractures are not exposed
 - d. Rigid fixation with vascularized tissue coverage is necessary for bone healing
 - e. Fractures of the lower leg are usually classified by the Gustilo system (Table 7-1)
 - i. Type I and II fractures usually have a good outcome with varied treatment
 - ii. Gustilo Type III injuries have a worse prognosis

Gustilo Classification of Open Fractures of the Lower Leg

Type I	Open tibial fracture with a wound less than one centimeter
Type II	Open tibial fracture with a wound greater than one centimeter, without extensive soft tissue damage
Type IIIA	Open tibial fracture with adequate soft-tissue coverage despite extensive laceration or flaps, or high-energy injury accompanied by any size wound
Type IIIB	Open tibial fracture, extensive soft-tissue loss with periosteal stripping and bone exposure
Type IIIC	Open tibial fracture with arterial injury requiring repair

Table 7-1

- f. Depending on the level of injury, different muscle flaps can be used to close the wounds
 - i. Proximal 1/3 of tibia
 - ii. Medial head of the gastrocnemius muscle
Lateral head of the gastrocnemius muscle
Proximally based soleus
 - iii. Middle 1/3 of tibia
Proximally based soleus
Flexor digitorum longus muscle
Extensor hallucis longus muscle

- iv. Lower 1/3 of tibia
Microvascular free tissue transfer
- g. Fasciocutaneous flaps such as reverse sural flap are another alternative for closure of difficult wounds in the lower leg
- 3. Foot
 - a. Split thickness skin grafts should be used if bone not exposed
 - b. The heel may be covered by medial or lateral plantar artery flaps
 - c. Weight bearing surface of foot ideally reconstructed with flaps that maintain protective sensibility such as medial or lateral plantar artery flaps that are innervated and taken from non-weight bearing arch
 - d. Forefoot - toe fillet and plantar digital flaps
- 4. The technical feasibility of lower extremity reconstruction must be weighed against the option of amputation with early prosthesis fitting and ambulation. Extensive injuries may lead to rehabilitation and non-weight bearing of up to two years, and late complications may still require amputation. Loss of sensation to plantar surface of foot is a significant consideration for amputation.

III. LYMPHEDEMA

Lymphedema may be a congenital or acquired problem, and results in accumulation of protein and fluid in the subcutaneous tissue. It may be a very debilitating and disfiguring disease, and at this time has no good surgical answer

- A. Primary (idiopathic)
 - 1. Female: Male = 2:1
 - 2. Classification - depends on age of onset
 - a. Congenital - present at birth
 - i. Milroy's disease - familial autosomal dominant incidence
 - ii. 10% of all primary lymphedema
 - b. Lymphedema praecox
 - i. Usually a disease of females
 - ii. 80% of all primary lymphedema
 - iii. Appears at puberty or early adulthood
 - iv. Localized swelling on dorsum of foot that gets worse with activity
 - v. Meige's disease presents with significant symptoms of acute inflammation
 - c. Lymphedema tarda
 - i. Appears in middle or later life
 - 3. Diagnosis
 - a. By history - sometimes hard to discern a component of venous stasis from the lymphedema
 - b. Lymphangiogram - 70% have hypoplasia, 15% aplasia and 15% hyperplasia
- B. Secondary: Acquired - Usually secondary to pathology in the regional lymph nodes
 - 1. Wucheria bancrofti - number one cause of lymphedema worldwide
 - 2. Post traumatic or post surgical
 - 3. Secondary to regional node metastases
 - 4. Treatment
 - a. Nonoperative

- i. Preferable in most circumstances and many patients are managed quite well
- ii. Elevation and elastic support are the mainstays of therapy - intermittent compression machines may be of benefit
- iii. Use of steroids controversial
- iv. Benzopyrones may be of benefit in high protein lymphedema
- v. Antiparasitic medications are indicated when appropriate
- vi. Systemic antibiotics and topical antifungal medications are often required
- b. Surgical management
 - i. Ablative procedures - usually involve excision of tissue and closure with a flap or skin graft
 - ii. Attempted re-establishment of lymphatic drainage by microvascular techniques has shown early improvement, but is prone to high late failure rate. May offer hope for patients with secondary lymphedema in the future

CHAPTER 7 - BIBLIOGRAPHY**LOWER EXTREMITY**

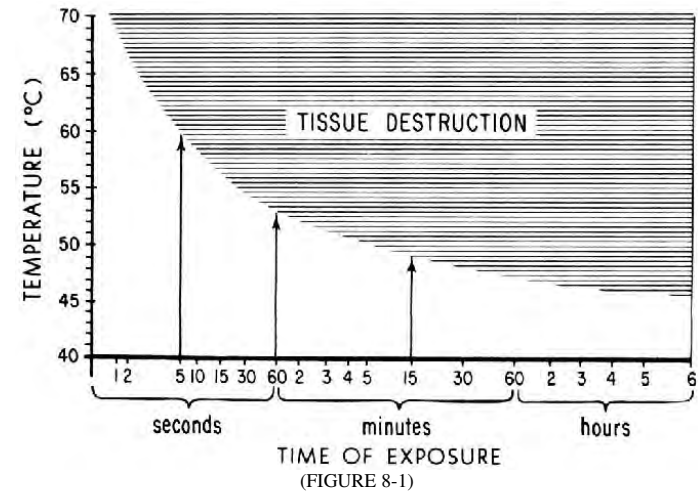
1. Heller, L. and Levin, S.L. Lower extremity microsurgical reconstruction. *Plast Reconstr Surg.* 2001; 108:1029-41.

CHAPTER 8**THERMAL INJURIES**

Thermal injuries from heat, chemical reactions, electricity, or cold can result in destruction of the skin and cause local and systemic effects. The management of the patient with a major thermal injury requires understanding of the pathophysiology, diagnosis, and treatment not only of the local skin injury, but also of the derangements that occur in hemodynamic, metabolic, nutritional, immunologic, and psychologic homeostatic mechanisms.

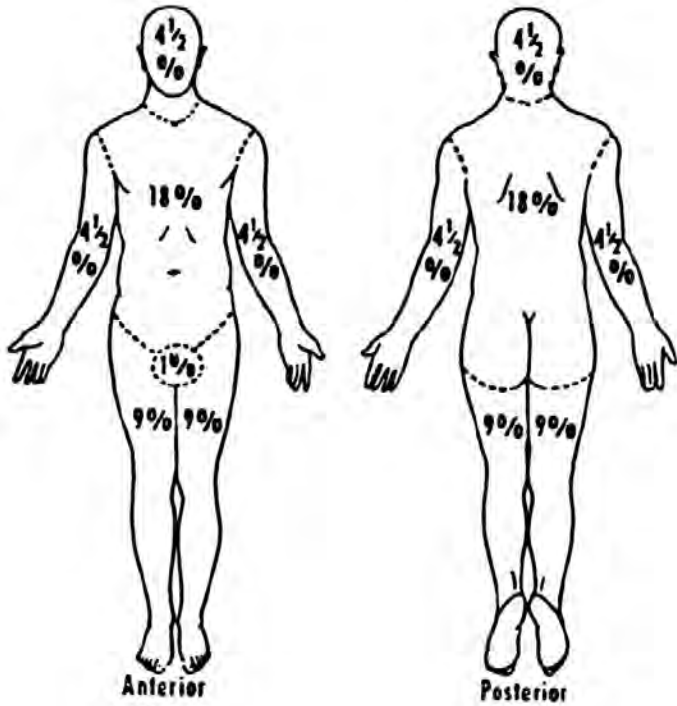
I. BURNS

- A. Pathophysiology: Amount of tissue destruction is based on temperature ($> 40^{\circ}\text{C}$) and time of exposure (Fig. 8-1)



B. Diagnosis and prognosis

1. Burn size: % of total body surface area (TBSA) burned
 - a. Rough estimate is based on rule of 9's (Fig. 8-2)
 - b. Different charts are required for adults and children because of head-chest size discrepancy and limb differentials for ages birth to seven years (Fig. 8-3 and 8-4)



(FIGURE 8-2)

BURN SHEET

NAME _____ AGE _____ NUMBER _____
 BURN RECORD. AGES - BIRTH - 7 1/2 DATE OF OBSERVATION _____

— 1st DEGREE
 — 2nd DEGREE
 — 3rd DEGREE

AREA	AGE 0	1	5
A 1/2 OF HEAD	9 1/2	8 1/2	6 1/2
B 1/2 OF ONE THIGH	2 1/2	3 1/4	4
C 1/2 OF ONE LEG	2 1/2	2 1/2	2 1/2

% BURN BY AREAS

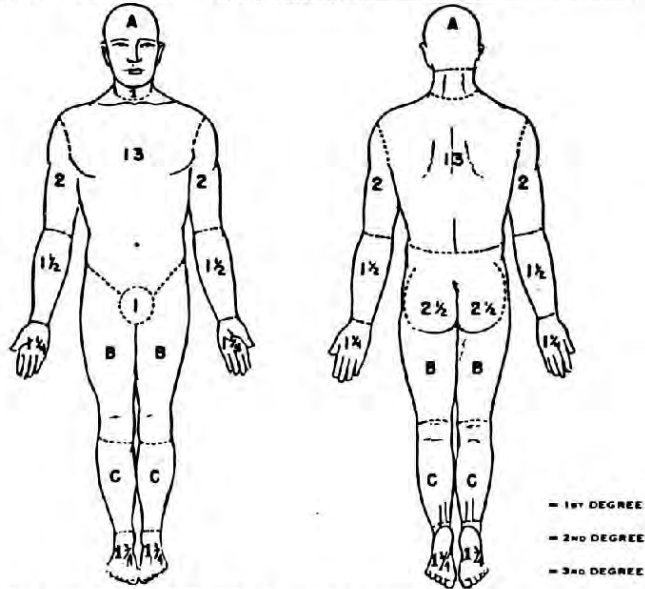
PROBABLE 3rd° BURN	HEAD _____	NECK _____	BODY _____	UP ARM _____	FOREARM _____	HANDS _____
	GENITALS _____	BUTTOCKS _____	THIGHS _____	LEGS _____	FEET _____	
TOTAL BURN	HEAD _____	NECK _____	BODY _____	UP ARM _____	FOREARM _____	HANDS _____
	GENITALS _____	BUTTOCKS _____	THIGHS _____	LEGS _____	FEET _____	

SUM OF ALL AREAS _____ PROBABLY 3rd° _____ TOTAL BURN _____

(FIGURE 8-3)

BURN SHEET

NAME _____ AGE _____ NUMBER _____
 BURN RECORD: AGES 7 TO ADULT. DATE OF OBSERVATION _____



RELATIVE PERCENTAGES OF AREAS AFFECTED BY GROWTH

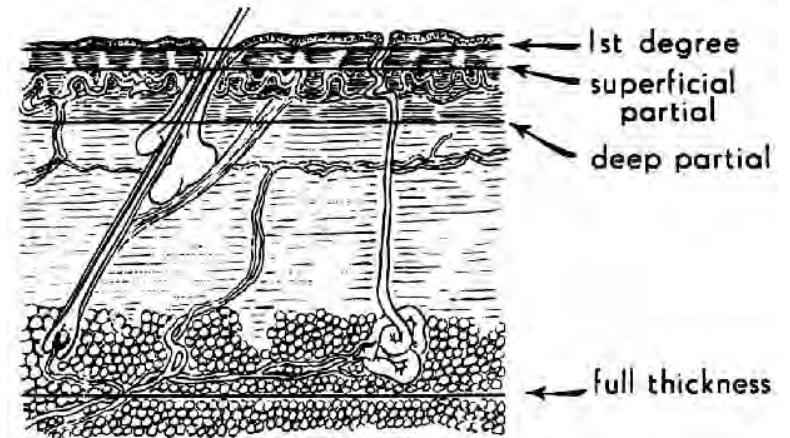
AREA	AGE 10	15	ADULT
A 1/2 OF HEAD	5 1/2	4 1/2	3 1/2
B 1/2 OF ONE THIGH	4 1/4	4 1/2	4 1/4
C 1/2 OF ONE LEG	3	3 1/4	3 1/2

% BURN BY AREAS

PROBABLE 3RD° BURN	HEAD _____	NECK _____	BODY _____	UP. ARM _____	FOREARM _____	HANDS _____
	GENITALS _____	BUTTOCKS _____	THIGHS _____	LEGS _____	FEET _____	
TOTAL BURN	HEAD _____	NECK _____	BODY _____	UP. ARM _____	FOREARM _____	HANDS _____
	GENITALS _____	BUTTOCKS _____	THIGHS _____	LEGS _____	FEET _____	

(FIGURE 8-4)

2. Age: burns at the extremes of age carry a greater morbidity and mortality
3. Depth: difficult to assess initially (injury can evolve over 24-48 hours)
 - a. History of etiologic agent and time of exposure helpful
 - b. Classification (Fig. 8-5)
 - i. First degree: erythema but no skin breaks
 - ii. Second degree: blisters, red and painful
 - (a) Superficial partial-thickness, involves epidermis and upper dermis
 - (b) Deep partial-thickness, involves deeper dermis
 - iii. Third degree: full-thickness-insensate, charred or leathery
 - iv. Fourth degree: muscle, bone
 - c. Zones of injury
 - i. Coagulation (central): necrotic, irreparably injured
 - ii. Stasis (intermediate): vasoconstriction and ischemia (can improve or worsen)
 - iii. Hyperemia (peripheral): heals without scarring
4. Location: face and neck, hands, feet, and perineum may cause special problems and warrant careful attention; often necessitate hospitalization/burn center
5. Inhalation injury: beware of closed quarters burn, burned nasal hair, carbon particles in pharynx, hoarseness, conjunctivitis
6. Associated injuries, e.g. fractures



(FIGURE 8-5)

- 7. Co-morbid factors, e.g. pre-existing cardiovascular, respiratory, renal and metabolic diseases; seizure disorders, alcoholism, drug abuse
 - 8. Prognosis: best determined by burn size (TBSA) and age of patient, inhalation injury
 - 9. Circumferential burns: can restrict blood flow to extremity, respiratory excursion of chest and may require escharotomy
- C. Categorization of burns is used to make treatment decisions and to decide if treatment in a burn center is necessary (Table 8-1, Table 8-2)

Categorization of burns (American Burn Association)			
	Major Burn	Moderate Burn	Minor Burn
Size - Partial thickness	> 25% adults > 20% children	15-25% adults 10-20% children	< 15% adults < 10% children
Size - Full thickness	> 10%	2-10%	< 2%
Primary areas	major burn if involved	not involved	not involved
Inhalation injury	major burn if present or suspected	not suspected	not suspected
Associated injury	major burn if present	not present	not present
Co-morbid factors	poor risk patients make burn major	patient relatively good risk	not present
Miscellaneous	electrical injuries		
Treatment environment	usually specialized burn care facility	general hospital with designated team	often managed as out-patient

(Table 8-1)

Burns That Dictate Patient Admission to a Hospital or Burn Center
• 2° and 3° burns greater than 10% of BSA in patients under 10 or over 50 years of age
• 2° and 3° burns greater than 20% BSA in any age group
• 2° and 3° burns posing a serious threat of functional or cosmetic impairment, e.g. the face, hands, feet, genitalia, perineum, and about major joints)
• 3° burns greater than 5% BSA in any age
• Electrical burns including lightning
• Chemical burns posing a serious threat of functional or cosmetic impairment
• Inhalation injury
• Burns associated with major trauma

Table 8-2

- D. Treatment plan
1. History and physical exam
 2. Relieve respiratory distress - escharotomy and/or intubation
 3. Prevent and/or treat burn shock - IV - large bore needle (x2)
 4. Monitor resuscitation - Foley catheter and hourly urine output
 5. Treat ileus and nausea - N.G. tube if > 20% TBSA burn or intubated
 6. Tetanus prophylaxis
 7. Baseline laboratory studies (i.e. CBC, comprehensive metabolic panel, U/A, chest x-ray, EKG, cross- match, arterial blood gases, and carboxyhemoglobin)
 8. Cleanse, debride, and treat the burn wound
- E. Respiratory distress
1. Three major causes of respiratory distress in the burned patient:
 - a. Unyielding burn eschar encircling chest
 - i. Distress may be apparent immediately
 - ii. Requires escharotomy (cutting into the eschar to relieve constriction)
 - b. Carbon monoxide poisoning
 - i. May be present immediately or later
 - ii. Diagnosed by carboxyhemoglobin levels measured in arterial blood gas
 - iii. Initial Rx is displacement of CO by 100% O₂ by facemask
 - iv. Hyperbaric oxygen treatment may be of value
 - c. Smoke inhalation leading to pulmonary injury
 - i. Insidious in onset (18-36 hours)
 - ii. Due to incomplete products of combustion, not heat
 - iii. Causes chemical injury to alveolar basement membrane and pulmonary edema
 - iv. Initial Rx is humidified O₂ but intubation and respiratory support may be required

- v. Secondary bacterial infection of the initial chemical injury leads to progressive pulmonary insufficiency
- vi. Severe inhalation injury alone or in combination with thermal injury carries a grave prognosis
- vii. Three stages of presentation have been described:
 - (a) Acute pulmonary insufficiency (immediately postburn to 48 hours)
 - (b) Pulmonary edema (48-72 hours)
 - (c) Bronchopneumonia (25 days)
- viii. Monitor respiratory and mental status – be aware of hoarseness, wheezing, stridor

F. Burn shock

1. Massive amounts of fluid, electrolytes, and protein are lost from circulation almost immediately after burning (Table 8-3)

Burn or Associated Condition Dictating Extra Fluid Administration
<ul style="list-style-type: none"> • Underestimation of the %TBSA burn • Burn greater than 80%TBSA • Associated traumatic injury • Electrical burn • Associated inhalation injury • Delayed start of resuscitation • 4^o burn • Administration of osmotic diuretics • Pediatric burns

Table 8-3

2. Systemic response occurs if > 20% TBSA burn, resulting in a hypermetabolic state and capillary leak
3. Resuscitation requires replacement of sodium ions and water to restore plasma volume and cardiac output
 - a. Many formulas have been reported to achieve resuscitation
 - i. This can be given by prescribing 4cc Ringer's lactate/Kg/%TBSA burn over the first 24 hours (Baxter or Parkland Hospital formula)
 - ii. 1/2 of the first 24-hour fluid requirement should be given in the first eight hours postburn and the remaining 1/2 over the next 16 hours

- b. A plasma volume gap may remain – change to colloid after 24-30 hours postburn by administering plasma or 5% albumin 0.35-0.5cc/Kg/% TBSA burn over 24 hours; plasmapheresis may help
- c. After 30 hours D5W can be given at a rate to maintain a normal serum sodium

G. Monitoring resuscitation

1. Urine output 30-55cc/hr in adults and 1.2cc/Kg/hr in children < age 12
2. A clear sensorium, pulse < 120/min, HCO₃ > 18meq/L, cardiac output > 3.1 L/M²
3. Monitor for normothermia, blood pressure (mean arterial pressure > 60 in adults)
4. CVP in acute major burns is unreliable – use if myocardial disease, age > 65, inhalation injury, fluid requirements > 150% of expected

H. Metabolic considerations

1. Increased metabolic demands in patients with burn injury (hypermetabolic state)
2. High carbohydrate/high protein diet – dietician and tube feeds as needed
3. Early feeding (start at 12 hours) – prevents mucosal atrophy, ulceration, bacterial translocation in gut
4. Measure prealbumin to determine nutritional status

I. Treatment of the burn wound (Table 8-4)

1. Wound closure by the patient's own skin is the ultimate goal of treatment
 - a. By spontaneous healing
 - b. Autograft
 - c. Allograft
 - d. Xenograft
 - e. Artificial skin
 - f. Cultured epithelial cells
2. Specific treatment of the burn wound differs from one burn center to another
 - a. The most commonly employed topical antibacterials are silver sulfadiazine (Silvadene®) and mafenide acetate (Sulfamylon®)
 - b. Dressing changes 1x/day with soap and water – no need to scrub or remove blisters
 - c. Status of burn wound bacterial colonization and effectiveness of topical antibacterial treatment can be monitored by biopsies of wound for quantitative and qualitative bacteriology
 - d. Systemic antibiotic therapy only used for sepsis, not prophylactically (breeds resistant organisms)
 - e. resistant organisms)

Sample Orders	
For a 70 Kg 40 year old patient with a 40% flame burn:	
1.	Admit to ICU portion of burn center
2.	Strict bedrest with head elevated 45°
3.	Maintain elevation of burned extremities
4.	Vital signs: pulse, BP respiration q 15 min, temperature q 2 h
5.	Check circulation of extremities (capillary refill or Doppler) q 30 min
6.	100% O ₂ face mask
7.	Infuse Ringer's lactate at 700cc for first hour, then reassess
8.	Measure urinary output by Foley catheter to closed drainage
9.	Notify physician of first hour's urine output (must be 30-50cc: 1.2-1.5cc in pediatric patient)
10.	N.P.O.
11.	N.G. tube to intermittent low suction
12.	Measure pH of gastric content q 2 h — stress ulcer prophylaxis (e.g. Zantac)
13.	Morphine sulfate 4 mg intravenously q 2-3 hr prn pain - no intramuscular narcotics (unreliable absorption)
14.	Tetanus toxoid 0.5cc IM (if patient previously immunized)
15.	Send blood for Hct., glucose, BUN, cross match 2 units, electrolytes
16.	Urine for U.A. and culture
17.	Chest x-ray
18.	EKG
19.	Arterial blood gases q 6 h and prn
20.	Cleanse wounds with Betadine solution, debride all blisters, map injury on Lund-Browder chart, and photograph wounds
21.	Apply silver sulfadiazine to all wounds with sterile gloved hand (use reverse isolation technique when burn wounds are exposed)
22.	Dress wounds with burn gauze and surgifix
23.	Splint extremities as per physical therapist
24.	Change all dressings, cleanse wounds, and reapply topical antibacterial q 8 h or q 12 h
25.	Bronchoscopy — If inhalation injury suspected

Table 8-4

3. Necrotic tissues may be removed by any of several techniques (may take 5-7 days to declare):
 - a. Formal excision
 - b. Tangential (layered) debridement
 - c. Enzymatic debridement
 - d. Hydrotherapy - a useful adjunct
4. Autografts should be applied to priority areas first, such as the hands, face and important joints
5. Once healed, pressure is usually necessary with elastic supports to minimize hypertrophic scarring
6. Physical therapy - important adjunct in burn care
- J. Complications: can occur in every physiologic system or secondary to burn injury (Table 8-5)
 1. Renal failure
 - a. From hypovolemia
 - b. Beware of nephrotoxic antibiotics in the burn patient

Risk Factors in Burn Wound Infection	
I.	PATIENT FACTORS
A.	Extent of burn > 30% of body surface
B.	Depth of burn: full-thickness vs. partial-thickness
C.	Age of patient (very young or very old at higher risk)
D.	Pre-existing disease
E.	Wound dryness
F.	Wound temperature
G.	Secondary impairment of blood flow to wound
H.	Acidosis
II.	MICROBIAL FACTORS
A.	Density >10 ⁸ organisms per gram of tissue
B.	Motility
C.	Metabolic products <ol style="list-style-type: none"> 1. Endotoxin 2. Exotoxins 3. Permeability factors 4. Other factors
D.	Antimicrobial resistance

Table 8-5

2. Gastrointestinal bleeding
 - a. More likely in burns over 40% TBSA
 - b. Usually remains subclinical
 - c. Antacids and H₂ blockers
 - d. Increased risk with burn wound sepsis
3. Burn wound sepsis
 - a. Monitored by tissue biopsy - qualitative and quantitative
 - b. Must keep bacterial count < 10⁵ bacteria/gm of tissue
 - c. Clinically suspect sepsis with
 - i. Sudden onset of hyper or hypothermia
 - ii. Unexpected congestive heart failure or pulmonary edema
 - iii. Development of the acute respiratory distress syndrome
 - iv. Ileus occurring after 48 hours postburn
 - v. Mental status change
 - vi. Azotemia
 - vii. Thrombocytopenia
 - viii. Hypofibrinogenemia
 - ix. Hyper or hypoglycemia is especially suspect if burn > 40% TBSA
 - x. Blood cultures may be positive but in many cases are not
4. Progressive pulmonary insufficiency
 - a. Can occur after:
 - i. Smoke inhalation
 - ii. Pneumonia
 - iii. Cardiac decompensation
 - iv. Sepsis from any cause
 - b. Produces:
 - i. Hypoxemia
 - ii. Hypocarbica
 - iii. Pulmonary shunting
 - iv. Acidosis
5. Wound contracture and hypertrophic scarring
 - a. Largely preventable
 - b. Active range of motion of involved and adjacent joints is encouraged to prevent joint contractures from the outset
 - i. Splints and passive range of motion are used if active range of motion is unable to be performed, e.g. elbow and knee are kept in extension and MCP joints of fingers in flexion
 - ii. Limb elevation and range of motion are useful for reducing edema and maintaining movement
 - c. Timely wound closure with adequate amounts of skin should largely eliminate these problems
 - d. Continued postoperative splinting and elastic pressure supports are of value in the remodeling of collagen with prevention of hypertrophic scars

II. CHEMICAL BURNS

- A. Pathophysiology
 1. Tissue damage secondary to a chemical depends on:
 - a. Nature of agent
 - b. Concentration of the agent
 - c. Quantity of the agent
 - d. Length of time the agent is in contact with tissue
 - e. Degree of tissue penetration
 - f. Mechanism of action
- B. Diagnosis
 1. Chemical burns are deeper than initially appear and may progress with time
 - a. Fluid resuscitation needs often underestimated
 - b. Watch for renal/liver/pulmonary damage
- C. Treatment
 1. Initial treatment is dilution of the chemical with tap water
 - a. Copious irrigation for 30 minutes
 - b. Exception – cement/concrete/powdered lye should be brushed off dry
 2. Special attention to eyes – after copious irrigation with saline, consult ophthalmologist
 3. After 12 hours initial dilution, local care of the wound with debridement, topical antibacterials, and eventual wound closure is same as for thermal burn
- D. Of particular note are:
 1. Gasoline
 - a. Excretion by lung
 - b. May cause large skin burn, if immersed
 - c. Watch for atelectasis, pulmonary infiltrates; surfactant is inhibited
 2. Phenol
 - a. Dull, gray color to skin, may turn black
 - b. Urine may appear smoky in color
 - c. Spray water on burn surface
 - d. Wipe with polyethylene glycol
 - e. Direct renal toxicity
 3. Hydrofluoric acid
 - a. Irrigate copiously with water
 - b. Subcutaneous injections of 10% calcium gluconate, or intraarterial infusion in extremities
 - c. Monitor EKG of patients - may become hypocalcemic
 - d. Pulmonary edema may occur if subjected to fumes
 4. White phosphorous burn
 - a. Do not allow to desiccate - may ignite
 - b. Each particle must be removed mechanically
 - c. Copper sulfate (2%) may counteract to make phosphorous more visible (turns black in color)
 - d. Watch for EKG changes (Q - T interval and S - T and T wave changes)
 - e. May cause hemoglobinemia and renal failure

III. ELECTRICAL INJURIES

- A. Pathophysiology
 1. Effects of passage of electric current through the body depend on:
 - a. Type of circuit
 - b. Voltage of circuit
 - c. Resistance offered by body
 - d. Amperage of current flowing through tissue
 - e. Pathway of current through the body
 - f. Duration of contact
 2. Tissue resistance to electrical current increases from nerve (least resistant) to vessel to muscle to skin to tendon to fat to bone
- B. Diagnosis
 1. Types of injury
 - a. Arc injury: localized injury caused by intense heat
 - b. Injury due to current
 - i. Due to heat generated as current flows through tissue
 - (a) Injury more severe in tissue with high resistance (i.e. bones)
 - (b) Vessels thrombose as current passes rapidly along them
 - ii. Effect of current may not be immediately seen
- C. Special effects of electrical injury
 1. Cardiopulmonary
 - a. Anoxia and ventricular fibrillation may cause immediate death
 - b. Early and delayed rhythm abnormalities can occur
 - c. EKG changes may occur some time after the burn in a delayed fashion
 2. Renal
 - a. High risk of renal failure due to hemoglobin and myoglobin deposits in renal tubules
 - i. Requires higher urine flow (75cc/hr in adults)
 - ii. Must alkalinize urine to keep hemoglobin and myoglobin in more soluble state
 - iii. Mannitol may be useful to clear heavy protein load
 3. Fractures:
 - a. Tetanic muscle contractions may be strong enough to fracture bones, especially spine
 4. Spinal Cord Damage
 - a. Can occur secondary to fracture or demyelinating effecting of current
 5. Abdominal effects
 - a. Intraperitoneal damage can occur to G.I. tract secondary to current
 6. Vascular effects
 - a. Vessel thrombosis progresses with time
 - b. Delayed rupture of major vessels can occur
 7. Cataract formation - late complication
 8. Seizures
- D. Treatment
 1. CPR if necessary
 2. Fluids - usually large amounts

- a. No formula is accurate because injury is more extensive than can be predicted by skin damage
- b. Alkalinize with NaHCO_3 , if myoglobinuria or hemoglobinuria present
3. Monitoring
 - a. CVP or pulmonary wedge pressure helpful since total capillary leak does not occur as it does in a in thermal burn
 - b. Maintain urine output at 75-100cc/hr until all myoglobin and/or hemoglobin disappears from urine
4. Wound Management
 - a. Topical agent with good penetrating ability is needed [i.e. silver sulfadiazine (Silvadene®) or mafenide acetate (Sulfamylon®)]
 - b. Debride non-viable tissue early and repeat as necessary (every 48 hrs) to prevent sepsis
 - c. Major amputations frequently required
 - d. Technicium-99 stannous pyrophosphate scintigraphy may be useful to evaluate muscle damage
5. Treat associated injuries (e.g. fractures)

IV. COLD INJURIES

The two conditions of thermal injury due to cold are local injury (frostbite) and systemic injury (hypothermia)

- A. Frostbite
 1. Pathophysiology
 - a. Formation of ice crystals in tissue fluid
 - i. Usually in areas which lose heat rapidly (e.g. extremities)
 - b. Anything which increases heat loss from the body such as wind velocity, or decreases tissue perfusion, such as tight clothing, predisposes the patient to frostbite
 - c. Ability of various tissues to withstand cold injury is inversely proportional to their water content
 2. Treatment
 - a. The key to successful treatment is rapid rewarming in a 40° C water bath
 - i. Admission to hospital usually required
 - (a) Tetanus prophylaxis
 - (b) Wound management
 - (c) Physical therapy
 - (i) Maintenance of range of motion important
 - (ii) Daily whirlpool and exercise
 - (d) Sympathectomy, anti-coagulants, and early amputation of questionable value in controlled studies
 - ii. Usually wait until complete demarcation before proceeding with amputations. Non-viable portions of extremities will often autoamputate with good cosmetic and functional results.
- B. Hypothermia
 1. Diagnosis
 - a. Core temperature < 34° C

- b. Symptoms and signs mimic many other diseases
- c. High level of suspicion necessary during cold injury season
- 2. Treatment
 - a. Must be rapid to prevent death
 - b. Monitor EKG, CVP, and arterial blood gases and pH during warming and resuscitation, maintain urine output of 50cc/hr
 - c. Begin Ringer's lactate with 1 ampule NaHCO₃
 - d. Oral airway or endotracheal tube if necessary
 - e. Rapidly rewarm in 40° C hydrotherapy tank (requires 1-2 hours to maintain body temperature at 37°C)
 - f. Treat arrhythmias with IV Lidocaine or Amiodarone drip if necessary
 - g. Evaluate and treat any accompanying disease states

V. LIGHTNING INJURIES

- A. Cutaneous effects - lightning strikes may cause cutaneous burn wounds
 - 1. Contact burns from clothing on fire or contact with hot metal (i.e. zippers, etc)
 - 2. Entry and exit burns are usually small, may be partial or full thickness
 - 3. Lightning burns are not the same as electrical burns – don't get deep tissue injury
- B. May have temporary ischemic effects on extremity - pallor or neurologic deficits. Spontaneous recovery after a few hours is the rule - probably due to local vasoconstriction
- C. Systemic effects can occur such as arrhythmias, cataracts, CNS symptoms

CHAPTER 8 - BIBLIOGRAPHY

THERMAL INJURIES

1. Gallagher J.J., Wolf S.E., and Herndon D.N. Burns. In: Sabiston's Textbook of Surgery, 18th edition, eds. Townsend C.M., Beauchamp R.D., Evers B.M., et al. Philadelphia: Saunders, 2007.
2. Gibran N. Burns. In: Greenfield's Surgery Scientific Principles and Practice, 5th edition, eds. Mulholland M.W., Lillemoe K.D., Doherty G.M., et al. Philadelphia: Lippincott Williams and Wilkins, 2010.
3. Gibran, N.S. and Heimbach, D.M. Current status of burn wound pathophysiology. Clin Plast Surg. 2000; 27:11-22.
4. Grunwald T.B. and Garner W.L. Acute Burns. Plast Reconstr Surg. 2008; 121: 311e-319e.
5. Klein M.B., Nathens A.B., Emerson D., et al. An analysis of the long-distance transport of burn patients to a regional burn center. J Burn Care Res. 2007; 28:49- 55.
6. Matthews, M.S. and Fahey, A.L. Plastic surgical considerations in lightning injuries. Ann Plast Surg. 1997; 39:561-5.
7. van Zuijlen, P.P. et al. Dermal substitution in acute burns and reconstructive surgery: a subjective and objective long-term follow-up. Plast Reconstr Surg. 2001; 108: 1938-46.

CHAPTER 9

AESTHETIC SURGERY

Aesthetic surgery includes those procedures that enhance one's appearance to improve one's self-esteem. Patient goals should be realistic and their motivation should be appropriate. If a patient has unrealistic expectations or a personality disorder, the surgeon should be prepared to refuse to accept the patient or to refer the patient for psychiatric evaluation.

There are many valid reasons for seeking aesthetic surgery. A teenager may desire a more pleasing nose, a young woman may want her breasts enlarged so she is able to wear certain clothing, a balding man may want his hair restored, an older individual may want to have a more youthful appearance with a facelift, etc. The common denominator of these examples is the reasonable desire to improve one's outward appearance for oneself rather than for another person or reason.

If patients are selected carefully and their expectations are realistic, then well-executed surgical procedures generally will result in a happy patient and a gratified surgeon. The patient's self-image is improved and self-confidence is increased. If patients, on the other hand, are poorly selected, even if the procedure is performed flawlessly, the outcome may be tragic for both the patient and the surgeon. If the deformity is minimal and the concern of the patient is great, the chances for a successful outcome are small and the chance for an untoward result is great. Do not operate on these patients.

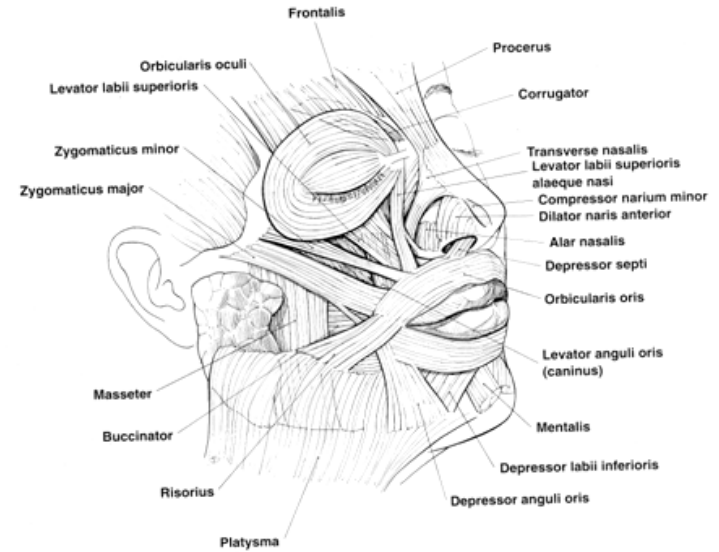
Commonly performed aesthetic surgical procedures can be classified in many ways. One way is by anatomic location.

I. FACIAL REJUVINATION

A. Facelift

1. Anatomy

- a. Facial Nerve trunk, rami, branches and their relations to surface landmarks
 - i. Innervation, position of muscle of facial expression
- b. Parotid gland/duct anatomy
- c. SMAS
 - i. **SMAS (superficial myoaponeurotic system):** superficial muscle-fascial layer in the head and neck; originating as the platysma in the neck extending superiorly as a thin layer of fascia just below the subcutaneous fat in the face and terminating superior to that as the superficial temporal fascia

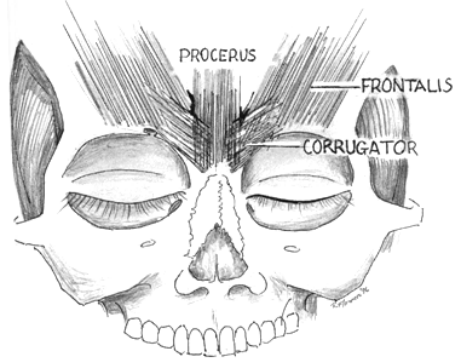


The muscles of facial expression

(FIGURE 9-1)

2. Operative Options
 - a. Skin Only
 - b. SMAS Plication/Excision Deep plane
 - c. Mini
3. Post-Operative Issues
 - a. Hematoma
 - b. Facial Nerve Injury
 - c. Scarring
 - d. Alopecia
- B. Upper Blepharoplasty
 1. Anatomy
 - a. Anterior Lamella
 - b. Posterior Lamella
 2. Pre-Operative Evaluation
 - a. Ptosis vs. Levator dysfunction

- C. Lower Blepharoplasty
 - 1. Operative Options
 - a. Transconjunctival
 - b. Sub-ciliary / transcutaneous
 - c. Canthopexy/Canthoplasty
 - d. Fat pads (medial, middle and lateral) need to be addressed
 - i. Removal or repositioning
- D. Brow Lift
 - 1. Operative Options
 - a. Endoscopic
 - i. Fixation techniques
 - ii. Cortical Tunnel
 - iii. Endotines ®
 - iv. Resorbable Screw fixation
 - b. Hairline incision
 - c. Browline

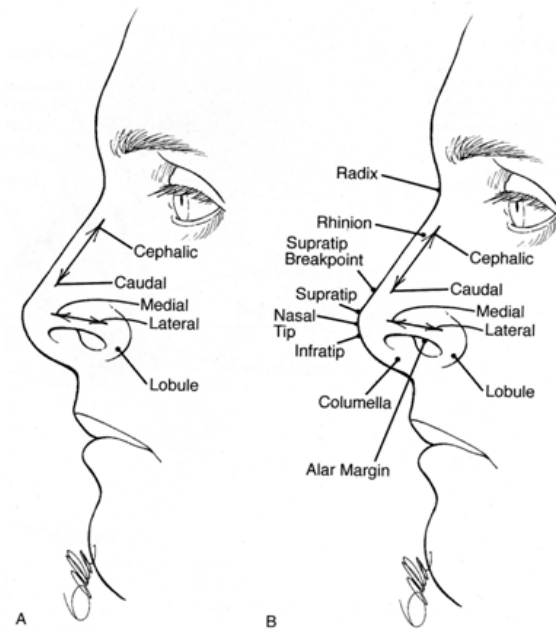


(FIGURE 9-2)

- E. Neck Lift
 - 1. Open
 - 2. Endoscopic
 - 3. Platysmal plication
 - 4. Lipectomy (direct or suction)
 - 5. Repositioning of submandibular glands
- F. Facial Augmentation
 - 1. Cheek Implants
 - 2. Fat Transfer

II. Rhinoplasty

- A. Terminology
 - 1. Rostral
 - 2. Caudal
- B. Anatomy
 - 1. Surface Anatomy
 - a. Supra-tip
 - b. Tip
 - c. Valves (internal and external)
 - d. Vascular supply
 - e. Innervation
 - f. Musculature



(FIGURE 9-3)

- C. Deformities
 - 1. Saddle nose
 - 2. Septal Deviation (Crooked nose)

III. Breasts

- A. Augmentation mammoplasty to increase size of breasts
 1. Incisions are made to keep scars as inconspicuous as possible, and may be located in the breast crease (inframammary fold), around the nipple (periareolar), or in the axilla. Breast tissue and skin is lifted to create a pocket for each implant
 2. The breast implant may be inserted under breast tissue or beneath the chest wall muscle
 3. After surgery, breasts appear fuller and more natural in contour. Scars will fade in time
- B. Mastopexy to reposition ptotic breasts
 1. Incisions outline the area of skin to be removed and the new position for the nipple
 2. Skin formerly located above the nipple is brought down and together to reshape the breast
 3. Sutures close the incision, giving the breast its new contour and moving the nipple to its new location
 4. After surgery, the breasts are higher and firmer, with sutures located around the areola, below it, and sometimes in the crease under the breast

IV. Soft Tissue Fillers

- A. Non-permanent
 1. Autologous
 - a. Fat
 - b. Dermafat grafts
 - c. Fascial grafts (ie - fascia lata)
 - d. Isologen
 - i. - A suspension cultured autologous fibroblasts harvested by skin biopsy of pt.
 2. Homologous
 - a. Alloderm®
 - i. acellular dermal graft is derived from skin obtained from tissue banks.
 - ii. can be micronized
 3. Human collagens
 - a. Cosmoderm®
 - b. Cosmoplast®
 4. Allograft
 - a. Bovine collagens
 - i. Zyderm®
 - ii. Zyplast®
 5. Synthetic
 - a. Radiesse™ (formerly marketed as Radiance™)
 - i. microspheres of calcium hydroxylapatite-based implant
 - ii. stimulate natural collagen growth, actually causing new tissue development
 - iii. is also useful in the treatment of facial lipoatrophy (a stigmatizing effect of HIV), vocal cord deficiencies, oral and maxillofacial defects, as well as scars and chin dimples

- b. Hyaluronic acid
 - i. Restylane® (Q-med)
6. Permanent
 - a. Artecoll /Artefil
 - i. polymethylmethacrylate spheres suspended in bovine collagen

V. Skin Rejuvenation

- A. Chemical peels for facial wrinkles
 1. Alphahydroxy acids – lightest peels
 2. Trichloroacetic acid – intermediate in strength
 3. Phenol/croton oil – most efficacious
 4. Chemical peel is especially useful for the fine wrinkles on the cheeks, forehead and around the eyes, and the vertical wrinkles around the mouth
 5. The chemical solution can be applied to the entire face or to a specific area – for example around the mouth – sometimes in conjunction with a facelift
 6. At the end of the peel, various dressings or ointments may be applied to the treated area
 7. A protective crust may be allowed to form over the new skin. When it's removed, the skin underneath will be bright pink
 8. After healing, the skin is lighter in color, tighter, smoother, younger looking
- B. Laser Resurfacing
 1. Laser surfacing is also used to improve facial wrinkles and irregular skin surfaces
 2. In many cases, facial wrinkles form in localized areas, such as near the eyes or around the mouth. The depth of laser of treatment can be tightly controlled so that specific areas are targeted as desired
 3. When healing is complete, the skin has a more youthful appearance
- C. Dermabrasion to improve raised scars or irregular skin surface
 1. In dermabrasion, the surgeon removes the top layers of the skin using an electrically operated instrument with a rough wire brush or diamond impregnated bur

CHAPTER 9 – BIBLIOGRAPHY**AESTHETIC SURGERY**

1. American Society of Plastic Surgeons. Statement on Liposuction. June 2000.
2. Clinics in Plastic Surgery. Selected issues.
 - a. Facial aesthetic surgery. 24:2, 1997.
 - b. Aesthetic laser surgery. 27:2, 2000.
 - c. New directions in plastic surgery, part I. 28:4, 2001.
 - d. New directions in plastic surgery, part II. 29:1, 2002.
3. LaTrenta, G. Atlas of Aesthetic Breast Surgery. New York: Elsevier Science, 2003.
4. Peck, G.C. and G.C., Jr. Techniques in Aesthetic Rhinoplasty. New York: Elsevier Science, 2002.
5. Plastic Surgery Educational Foundation. Patient Education Brochures, by topic. Arlington Heights, IL. 1-800-766-4955.
6. Rees, T.D. and LaTrenta, G.S. Aesthetic Plastic Surgery, 2 vol. New York: Elsevier Science, 1994.
7. Spinelli, H. Atlas of Aesthetic Eyelid Surgery. New York: Elsevier Science, 2003.
8. Coleman SR, Saboeiro AP. Fat grafting to the breast revisited: safety and efficacy. *Plast Reconstr Surg.* 2007 Mar;119(3):775-85; discussion 786-7

CHAPTER 10**BODY CONTOURING**

Body contouring is considered a component of Aesthetic surgery by utilization of techniques that will possibly enhance one's appearance. Additionally, these contouring procedures are utilized to improve one's general health, by the removal of chronically macerated, infected skin and subcutaneous tissues. There has been a dramatic rise in the number of body contouring procedures which correlates with the increased number of gastric bypass patients. These patients will generally have very dramatic weight loss, but have less elastic recoil of the skin. Massive weight loss patients are not simply left with familial fat bulges, but rather display aprons of excess skin. Two basic methods – liposuction and excisional surgery – are utilized for body contouring.

I. Liposuction

- A. Although liposuction may reduce cardiovascular risk, blood pressure, and fasting insulin levels, it should not be considered a weight loss procedure
- B. Best results are obtained when there is localized excess fat
- C. Generalized excess fat (mildly or moderately overweight) may still benefit, but assume potentially less dramatic results
- D. Skin elasticity is important for better results
- E. Men: If requesting abdominal wall liposuction need to be assessed carefully as fat excess in men tends to be intraabdominal. If requesting chest liposuction, consider a diagnosis of gynecomastia. Gynecomastia has three forms of histologic types: Glandular (amenable to suction assisted liposuction), Fibrous Type (ultrasound assisted liposuction), and Mixed.
- F. Cellulite: adipose deposits under the skin (superficial to Scarpa's fascia) that gives the skin a lumpy appearance and is predetermined by genetics. Contributing factors are hormones, pregnancy, and aging. Liposuction does not address cellulite and may worsen the appearance. Superficial liposuction should be approached with caution.
- G. The devices that are utilized in liposuction
 1. Suction: vacuum pumps for larger volumes and syringe suction for smaller volume
 2. Cannula: the instrument that is placed in the patient to remove the fat. The cannula will suck the collection of fat into the openings of the cannula, and when moved in and out, will amputate the fat. The fat then moves into the suction tubing and into the collection canister. These vary in length, diameter, and the configuration of the openings at the tip
 3. Collection Device: Usually a graduated canister, or for smaller volumes, a syringe. It is important to know how much is removed for symmetry and safety.
- H. Different Liposuction Techniques:
 1. Standard Liposuction: Cannula moved by the surgeon alone, suction applied by syringe or machine

- 2. Mechanical Assisted Liposuction (MAL): electric or pneumatic reciprocating cannula. These will cut the fat while suction is applied.
- 3. Ultrasound Assisted Liposuction (UAL): Pizeoelectrode in cannula causes cavitation of the adipose cell and disruption of the cell wall before suction. Increases risk for seroma and thermal injury of the skin. The surgeon will watch the total time of usage per site. Some devices combine the cavitation with suction, others require using a separate suction cannula after the ultrasound mode.
- 4. Laser Assisted Liposuction (LAL): energy disruption of the adipose prior to suction. Care must be taken to avoid thermal injuries to the tissues.
- I. Precise and accurate preoperative markings essential to quality results – mark topographically, estimate volumes to remove, mark areas to avoid. Discuss asymmetries with patient prior. Markings should be done with patient standing.
- J. Local Recommended doses: Lidocaine (<5mg/kg), Lidocaine with Epinephrine (<7mg/kg). Tumescent solutions of Lidocaine with Epinephrine with concentrations of 35-50mg/kg have been safely used due to slow absorption of anesthetic from fat, the persistent vasoconstriction from epinephrine, and lidocaine removed in the liposuction aspirate. Peak plasma concentrations of Lidocaine 10-12 hours after injection.

Operative Technique	Infiltrate	Estimate of Blood Loss (as a % of volume aspirated)
Dry	No infiltrate	20-45
Wet	200-300 cc's/area	4-30
Superwet	1 cc / 1 cc aspirate	<1
Tumescent	2-3 cc infiltrate per 1 cc aspirate	<1

(TABLE 10-1)

- K. Postoperative support garments often utilized
- L. It is recommended to admit patient to the hospital if removing greater than 5 Liters

II. Excisional Body Contouring Surgery

Designed to treat skin quality problems, laxity, panniculus formation, intertrigo, chronic back pain, upper extremity paresthesias, and cellulite

- A. Breast
 - 1. May involve breast reduction or mastopexy (breast lift procedure)
 - 2. Significant excess skin may require continuation of the scar onto the lateral chest wall or onto the back to remove the “dog ears”
 - 3. Repositions the nipple to the inframammary fold and re-supports ptotic breast tissue
 - 4. The ptotic breast (descended breast) may be deflated or devoid of volume and must be approached accordingly. The patient may need a mastopexy/augmentaion. Some

surgeons stage this due to the added complexity. Other surgeons have described using de-epithelialized skin medially and laterally to create an internal bra to support the inelastic tissue envelope.

- B. Arms
 - 1. Brachioplasty: Indicated for moderate to severe skin laxity of the arms with or without associated arm fat deposits.
 - 2. Mild skin laxity with fat deposits – consider liposuction instead of excision
 - 3. If skin laxity and fat deposits, combination of both.
 - 4. Mark with arms abducted 90 degrees
 - 5. May require incision onto the flank if excess extends onto the trunk
 - 6. Longitudinal (arm) incision line marked approximately 4 cm above and parallel to the medial bicipital sulcus toward medial epicondyle
 - 7. Inferior excision line estimated by pinch test or shift test, but final determination done in the operating room (tailor-tacking).
 - 8. Some surgeons close the skin as they cut each segment to prohibit edema and inability to close the arm. This is a dreaded complication that may require skin grafting.
 - 9. Avoid injury to the Medial Antebrachial Cutaneous Nerve (MABC)
 - 10. Axillary fascial anchoring sutures utilized to gain long term support. Pioneered by Lockwood.
 - 11. Gently compression with ace wraps often done. Patients instructed to elevate arms postoperatively. Some surgeons use drains while others do not.
- C. Abdomen - Panniculectomy vs. Abdominoplasty
 - 1. Panniculectomy - excision of excess apron of tissue alone. Does not plicate rectus abdominus diastasis. Does not involve umbilicus repositioning.
 - a. Usually performed to improve hygiene issues
 - b. Tissue under panniculus frequently macerated, ulcerated or infected
 - 2. Abdominoplasty – excision of excess abdominal skin and fat, and usually involves plication of the fascia for abdominal wall tightening / contouring, and transposition of the umbilicus. If the excess of skin is minor, the umbilicus may be floated to a slightly lower position.
 - 3. Abdominoplasty – Anterior vs. Circumferential (Belt Lipectomy)
 - 4. Anterior Abdominoplasty: Patient marked standing. Look for clinical hernias.
 - a. Removal of tissue frequently from the umbilicus to the pubis.
 - b. The tissue is undermined up to costal margins.
 - c. The abdominal wall fascia is usually plicated for rectus abdominus diastasis. May also plicate laterally to contour the waist.
 - d. The umbilicus is preserved on its stalk and delivered through the flap after caudal mobilization of the flap.
 - e. The closure involves the superficial fascial system and skin separately.
 - 5. Circumferential Abdominoplasty (Belt Lipectomy or Lower Body Lift):
 - a. Benefits patients with abdominal, flank, and posterior trunk skin excess and laxity.
 - b. The abdominal tissue is undermined and plicated as noted above.

- c. The excess lateral and posterior skin measured and marked preoperatively by pinch testing and the final excision volume is determined intraoperatively similar to brachioplasty (tailor-tacking).
- d. No direct or discontinuous undermining is performed over the buttocks

D. Medial Thigh Lift

1. Classic medial thigh lift plagued with problems such as inferior migration and widening of the scars, lateral traction deformities of the vulva, and early recurrence of the deformity
2. Results improved with suspension of the superficial fascial system to Colles fascia along the pubic ramus
3. May combine with liposuction at the same time, or liposuction prior in a staged fashion
4. Performed via a longitudinal elliptical excision along the medial thigh
5. Must change to a superficial dissection over the femoral triangle to prevent lymphedema
6. Closed similar to brachioplasty to prevent complications

E. Back

1. Direct excision of back rolls can be achieved
2. Excisions may be combined with Breast procedures as some patients have excess that courses laterally that is not breast tissue.

F. Buttock

1. Excision may be superior or inferior aspect of the buttock
2. Inferior excision may be camouflaged in the gluteal creases
3. Inferior tissue excision may lead to flattening of the buttock and an inferior buttock scar as opposed to crease
4. Excision may be combined with the lower body lift

III. Additive Body Contouring Procedures

- A. Breast: Can augment with alloplastic technique (silicone or saline implant) or autologous source (fat injection).
- B. Buttock: As above for breast. Can also auto-augment during lower body lift with dermoglandular flaps
- C. Other sites: Fat grafting in larger volumes increasingly used for many sites

CHAPTER 10 — BIBLIOGRAPHY

BODY CONTOURING

1. Achauer, BM, Eriksson, E, Guyuron, B, Coleman III, JJ, Russell, RC, and Vander Kolk, CA, Plastic Surgery Indications, Operations, and Outcomes, 5 vol. Mosby , 2000
2. Aston, SJ, Beasley, RW, and Thorne, CNM, Grabb and Smith's Plastic Surgery, Vol. 5, Lippincott-Raven, 1997
3. McCarthy, JG, Galiano, RD, Boutros SG, Current Therapy in Plastic Surgery, Saunders, Elsevier, 2006
4. Shestak, KG (editor) Abdominoplasty, Clinics in Plastic Surgery, 31 (4) October 2004